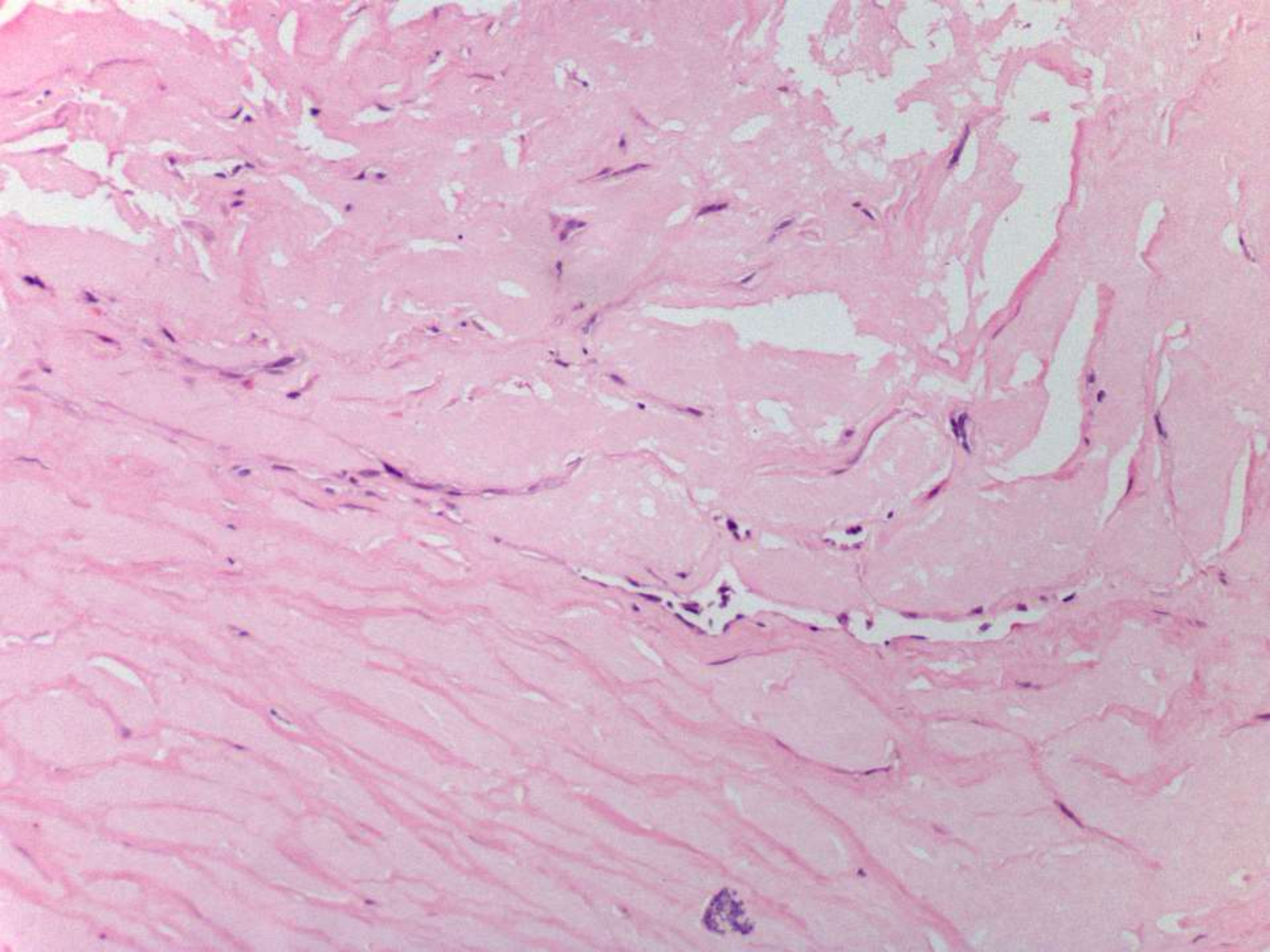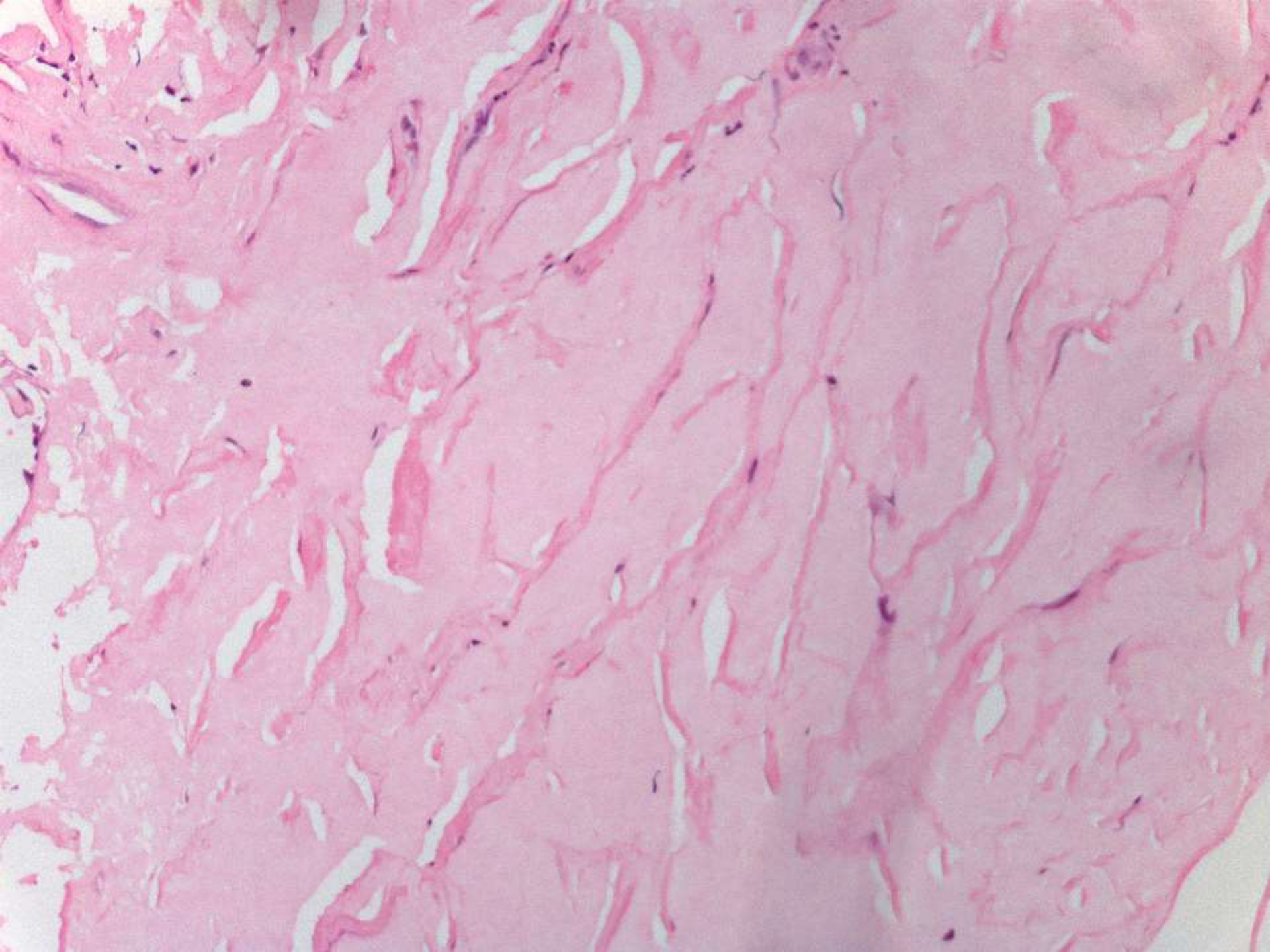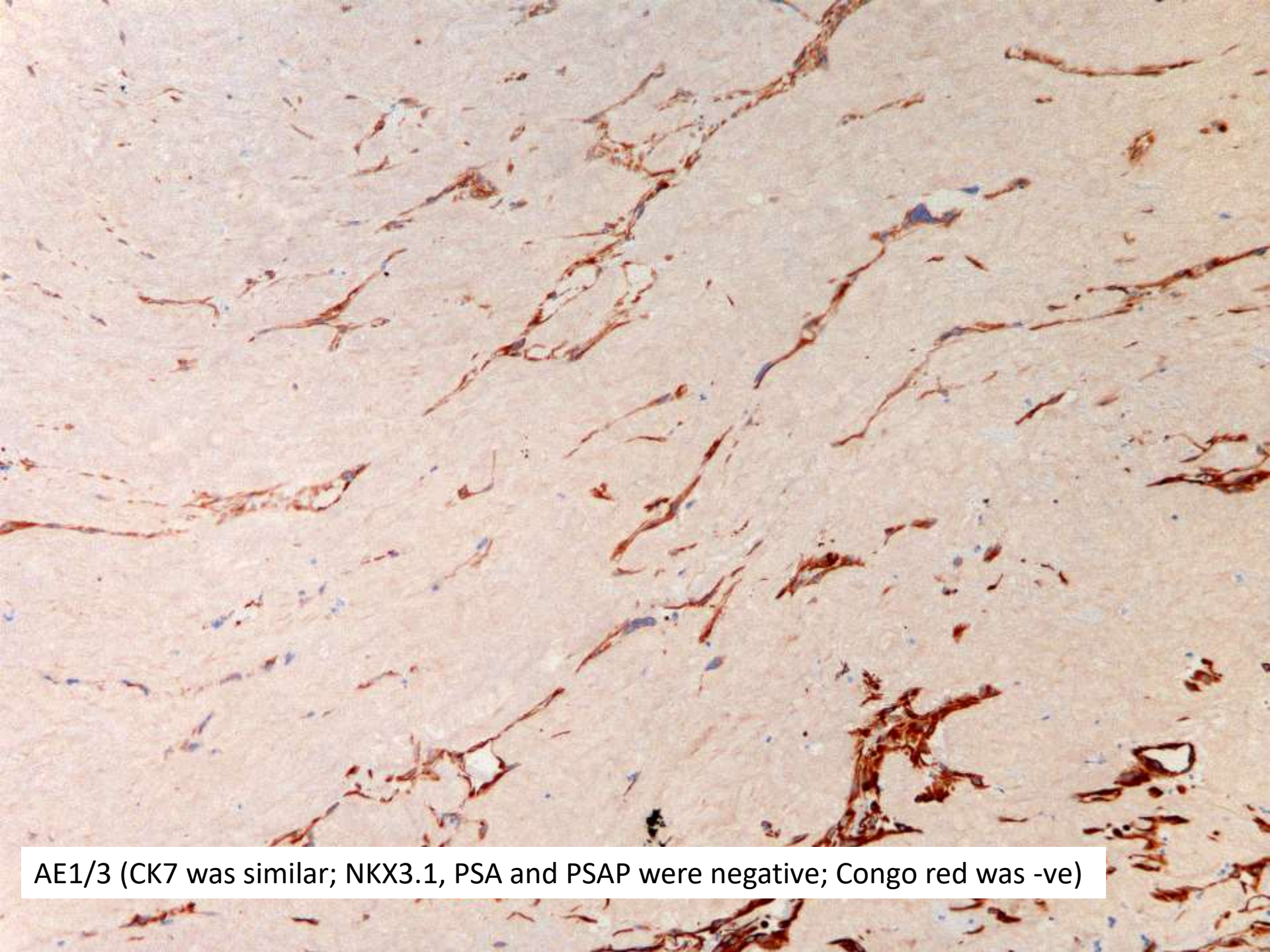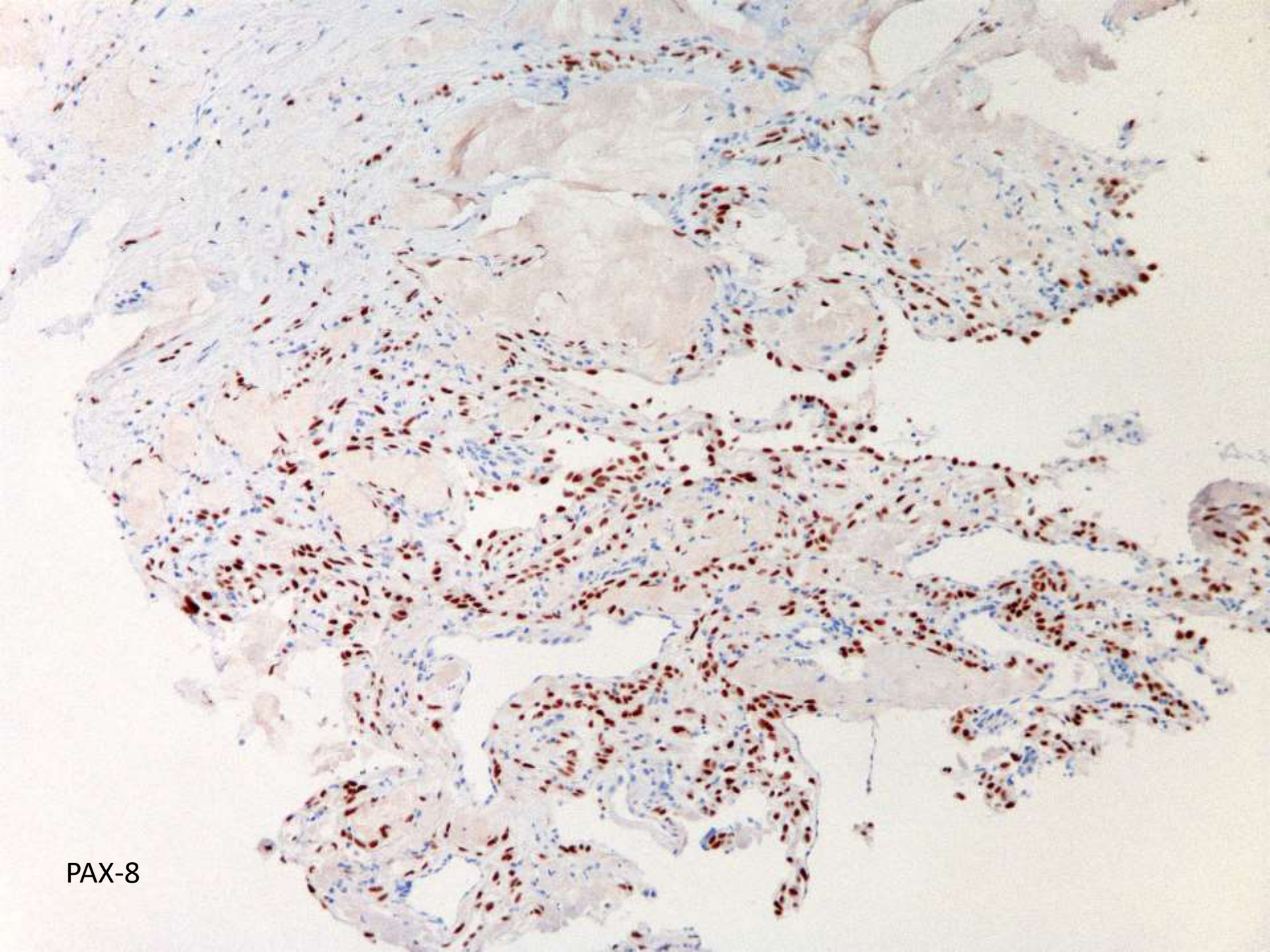
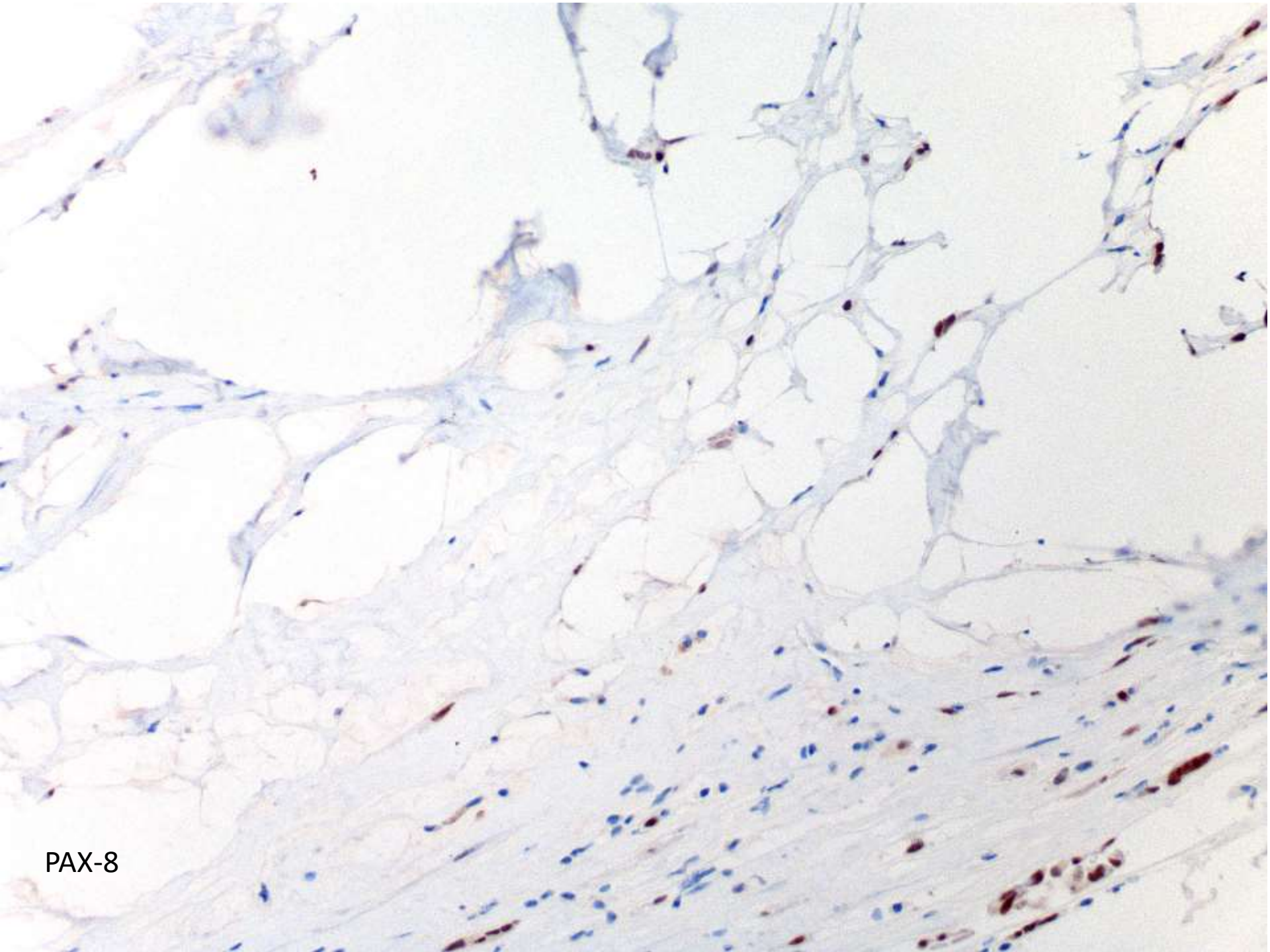


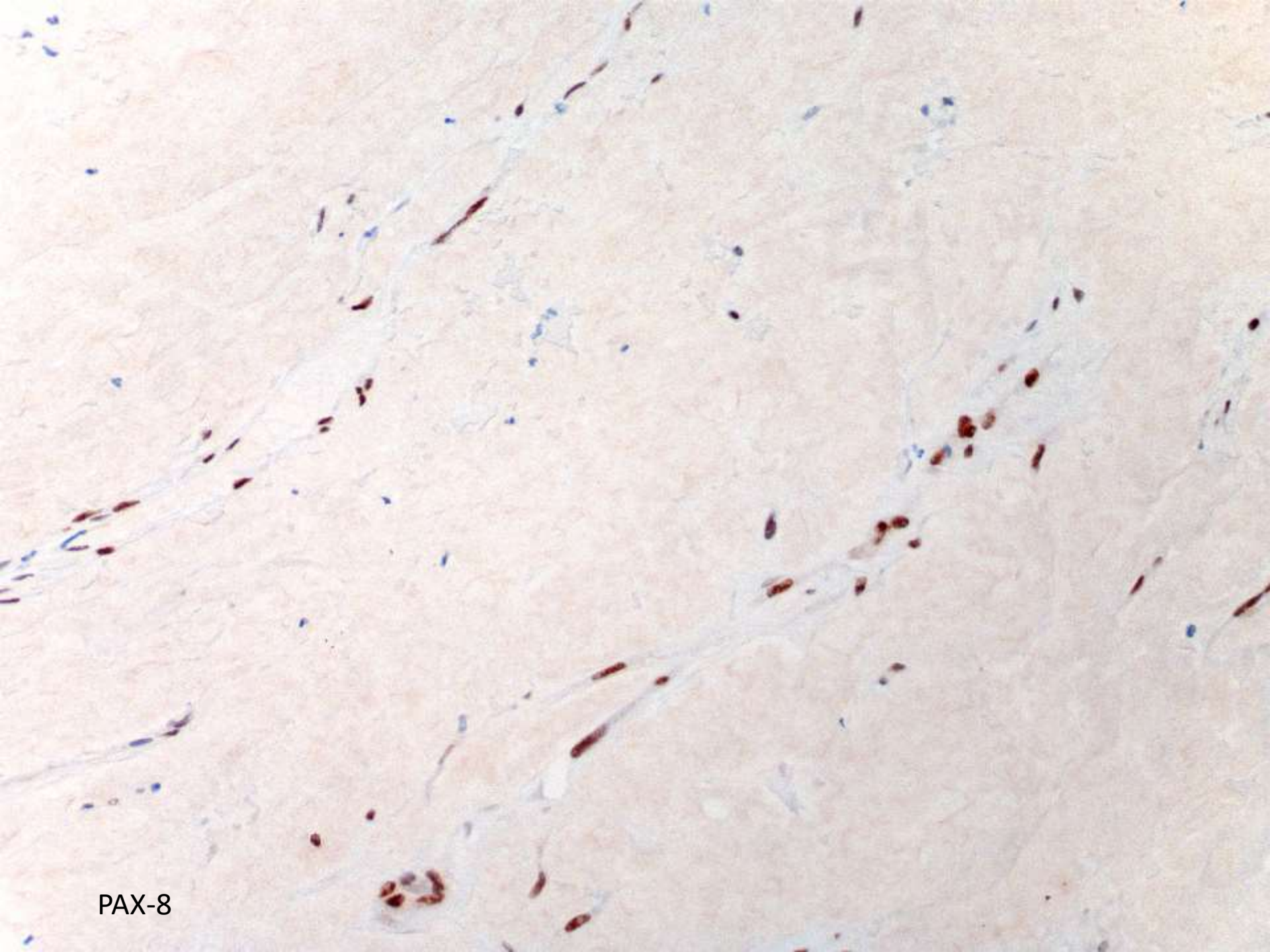
AE1/3 (CK7 was similar; NKX3.1, PSA and PSAP were negative; Congo red was -ve)



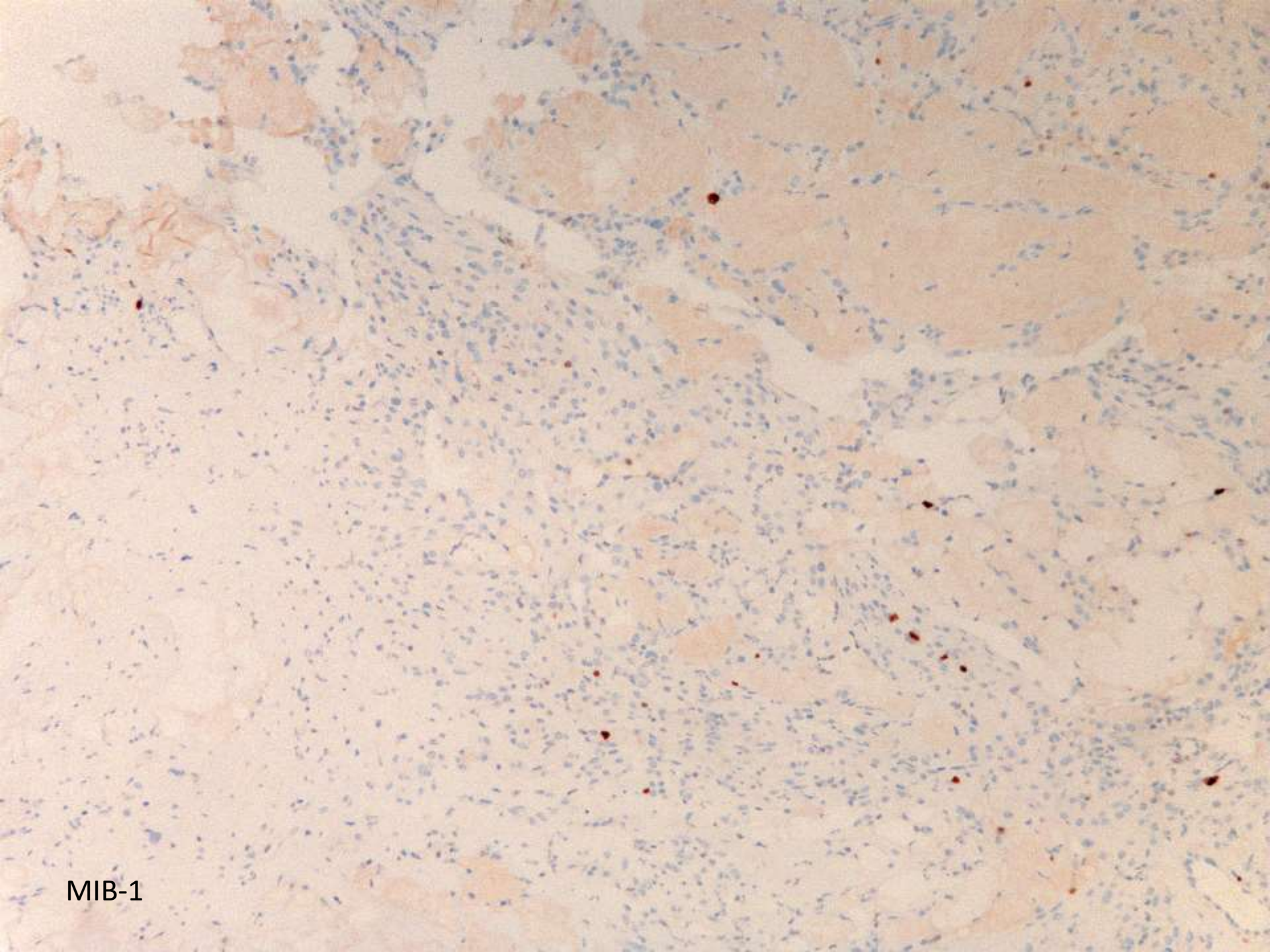
PAX-8



PAX-8



PAX-8



MIB-1

Fibromyxoid nephrogenic adenoma:  
a newly recognised variant  
mimicking mucinous  
adenocarcinoma Hansel DE *et al.*

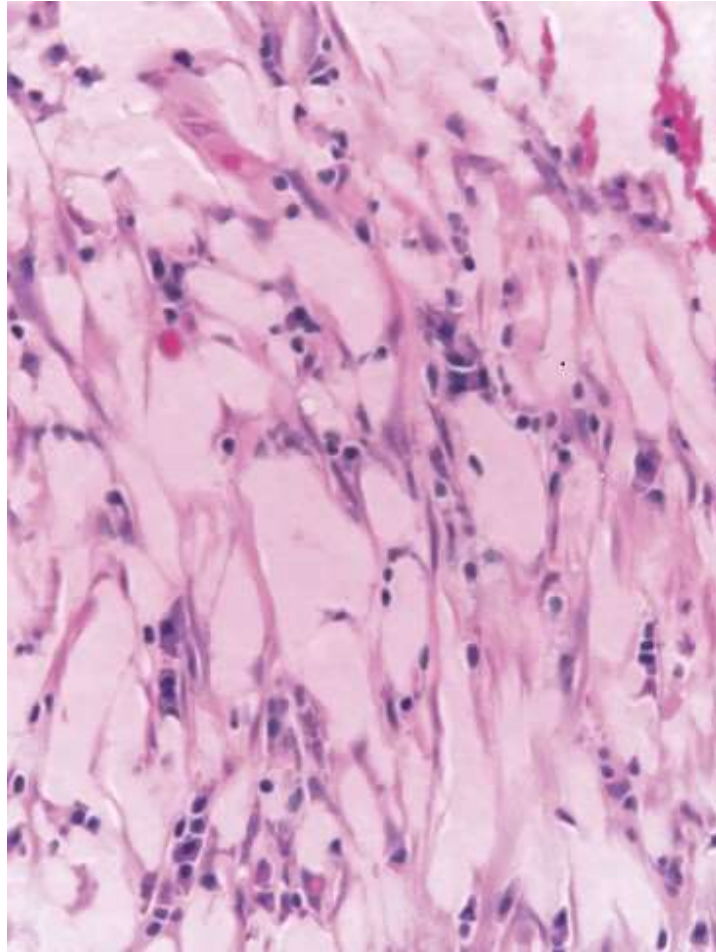
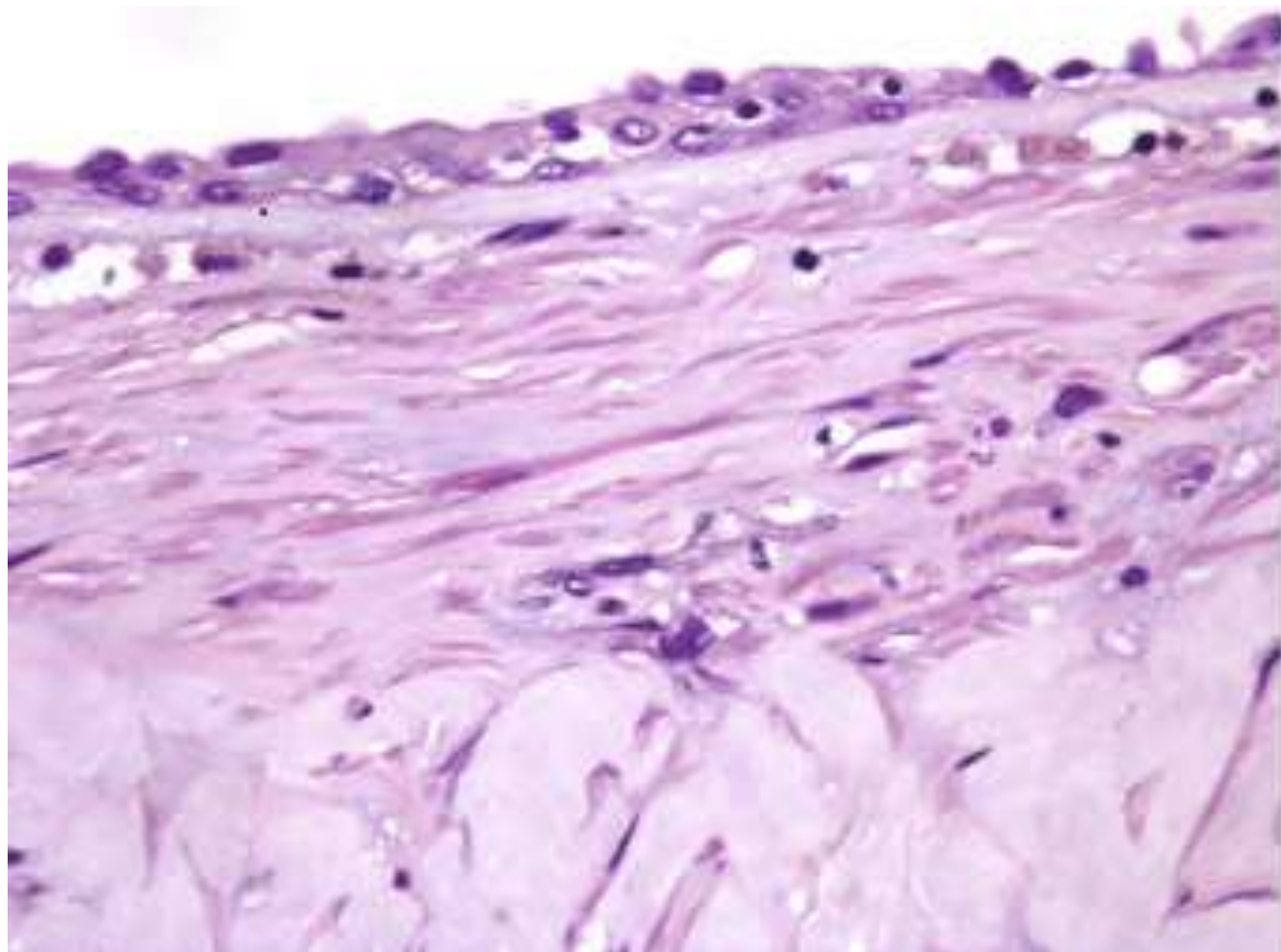


Image by Hansel DE



# Clear cell (adeno)carcinoma of urinary tract

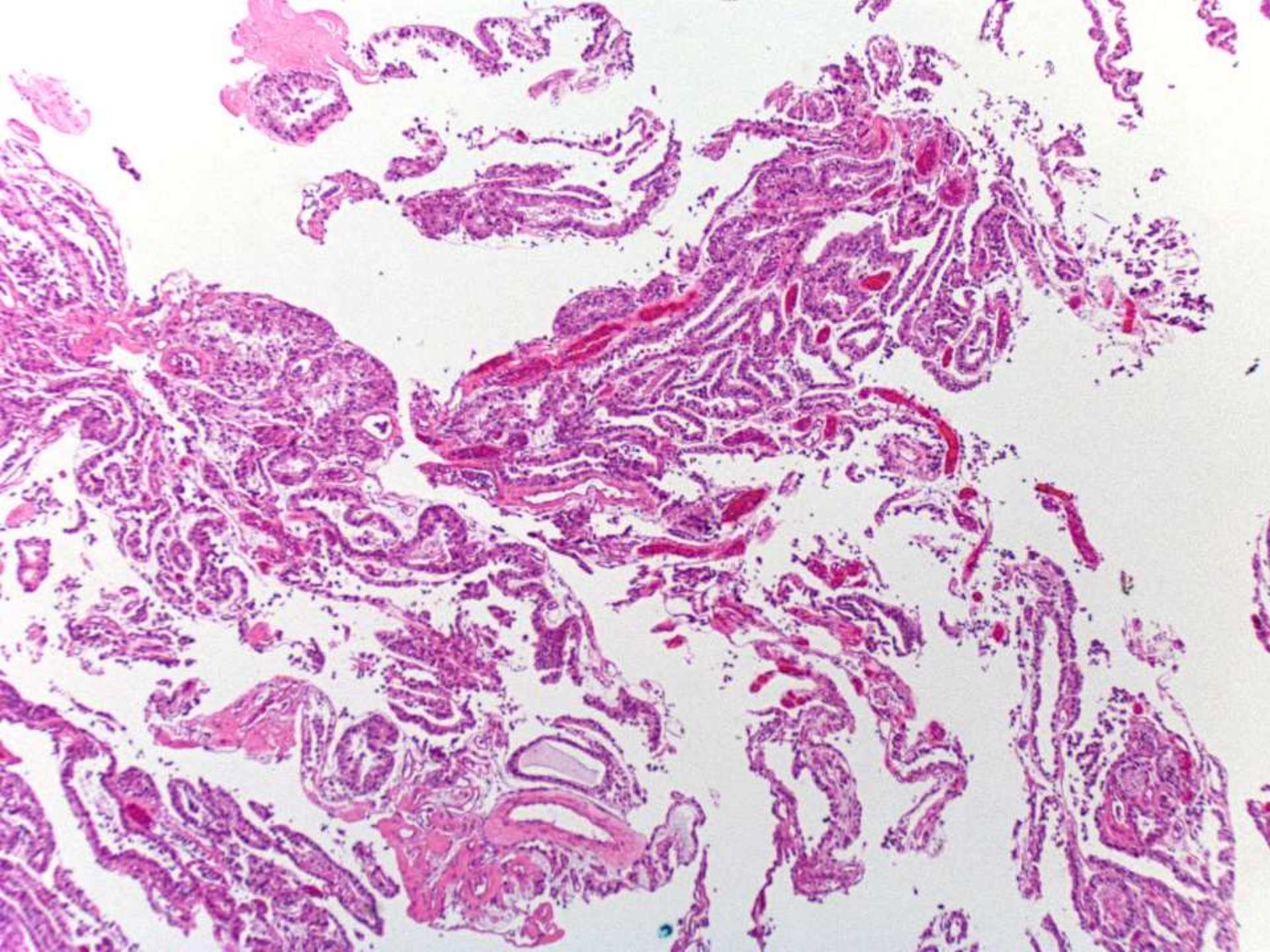
- F>>M
- Nephrogenic adenoma is a differential diagnosis, separated principally by morphology.
- **Beware lesions in urethral diverticula in females!**
- **Clear cell carcinoma may have a nephrogenic adenoma-like architecture at that location!**
- Clear cell carcinoma usually has at least moderate nuclear pleomorphism (but subtle in some cases); **easily found mitoses**, unlike nephrogenic adenoma, MIB-1 >5% (often 15-20%, or more in clear cell adenocarcinoma)
- Beware: both nephrogenic adenoma and clear cell adenocarcinoma are PAX8 positive. PAX8 also positive in some urothelial carcinoma e.g. some nested variant cases or in some cases in upper tract

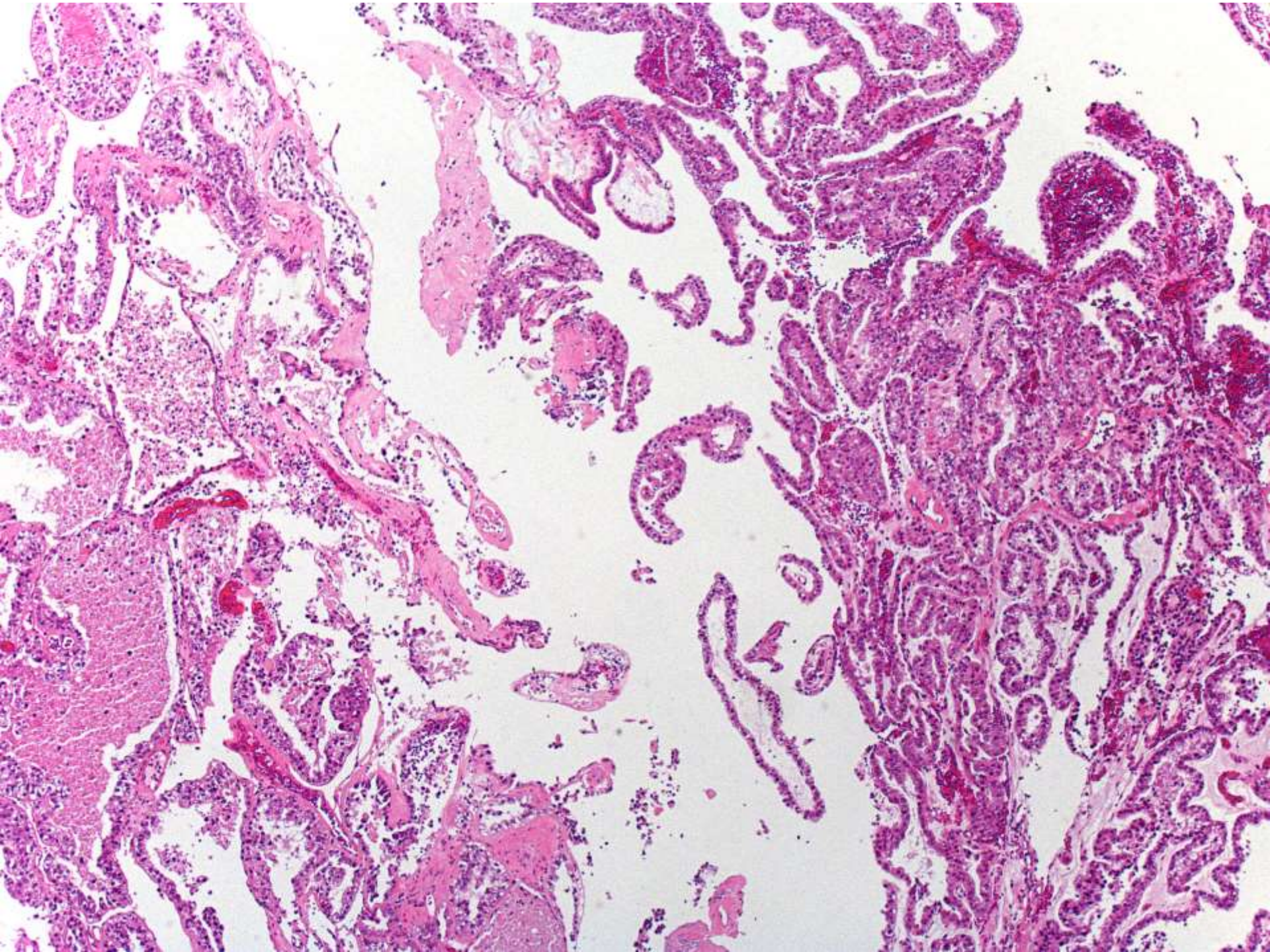
# References

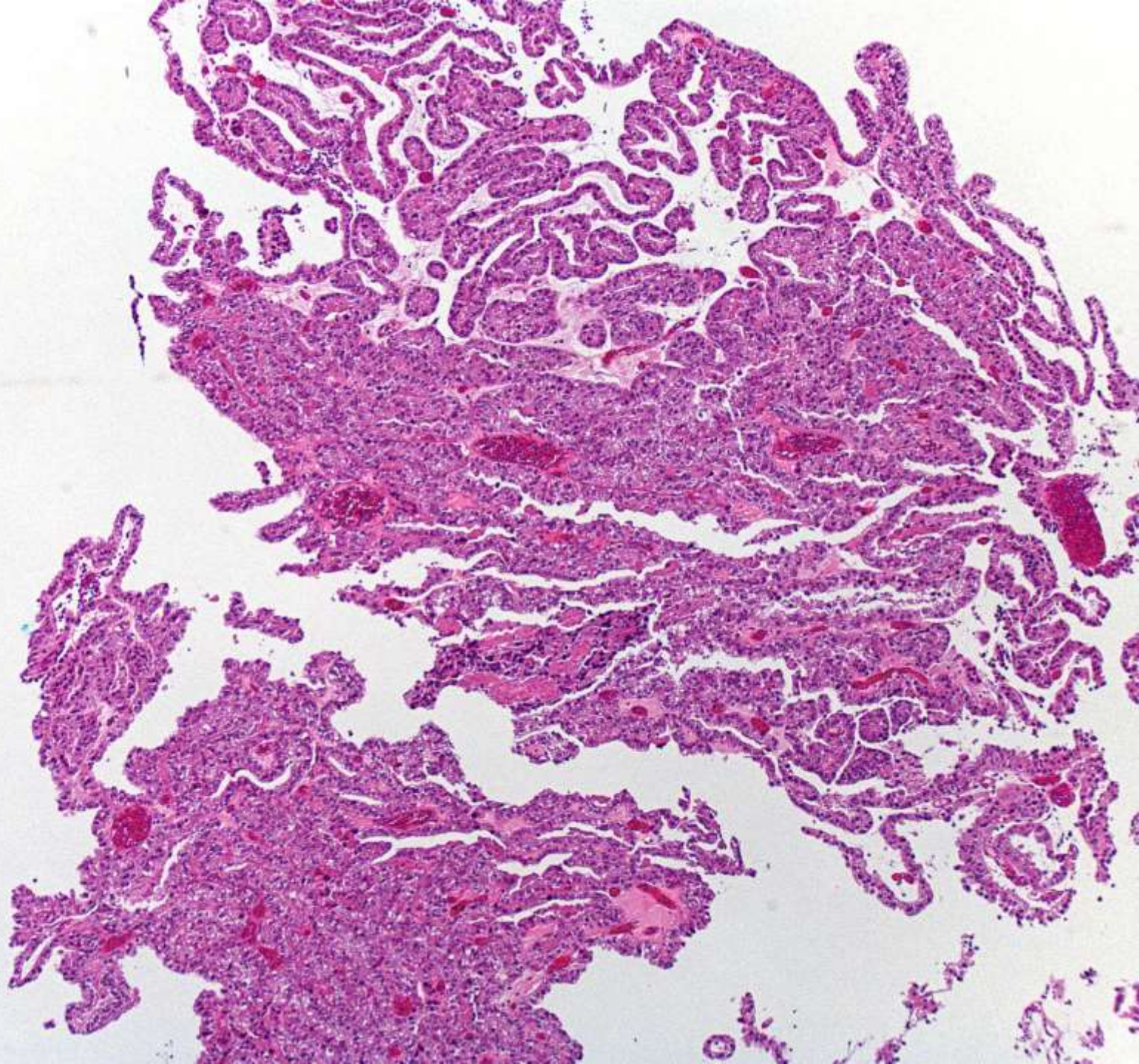
Clear cell adenocarcinoma of the urethra: a clinicopathologic analysis of 19 cases.

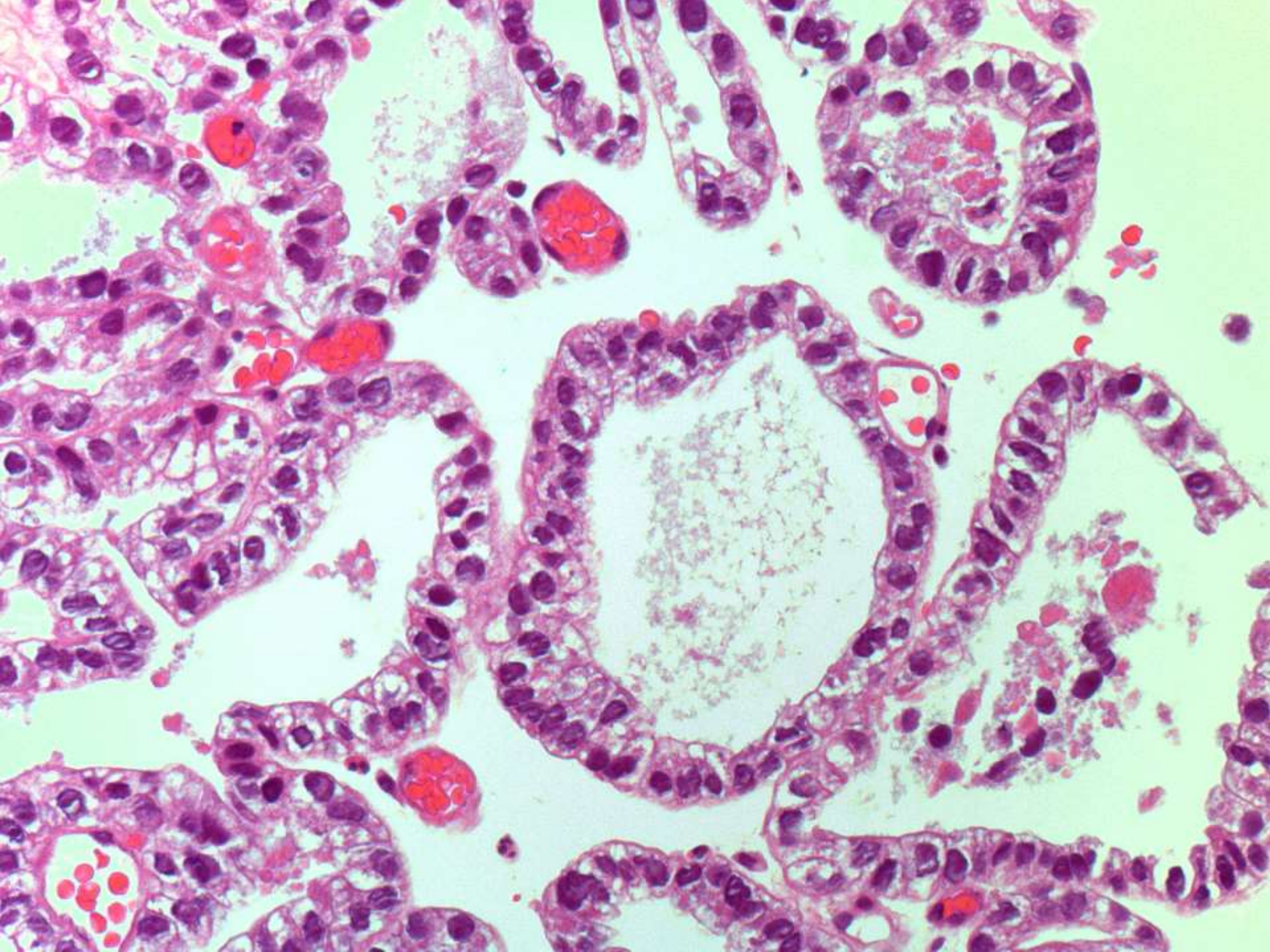
Oliva E and Young RH. *Mod Pathol*. 1996;9:513-520.

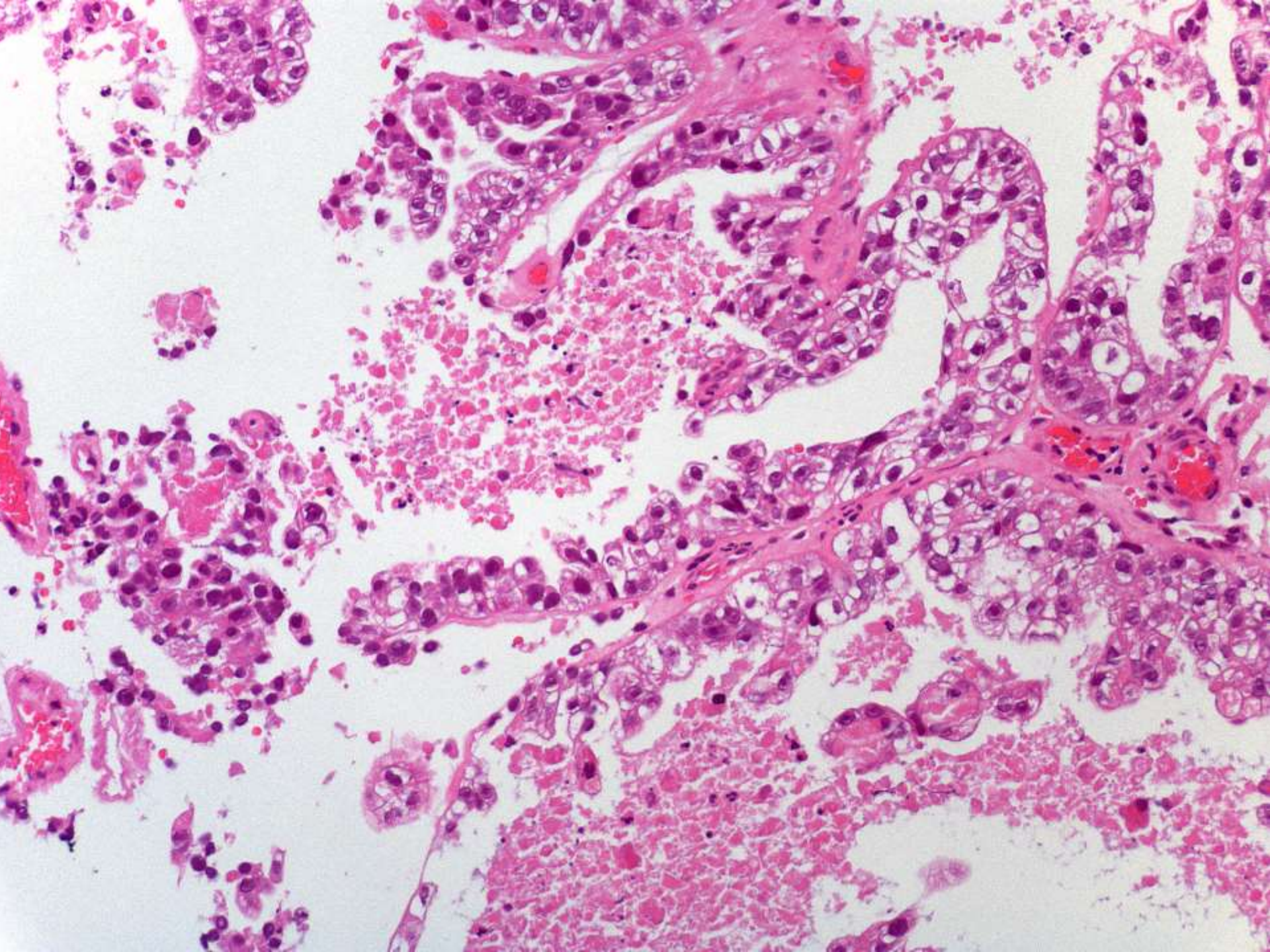
Clear cell adenocarcinoma of the bladder and urethra: cases diffusely mimicking nephrogenic adenoma. Herawi M *et al*. *Hum Pathol* 2010;41:594-601.

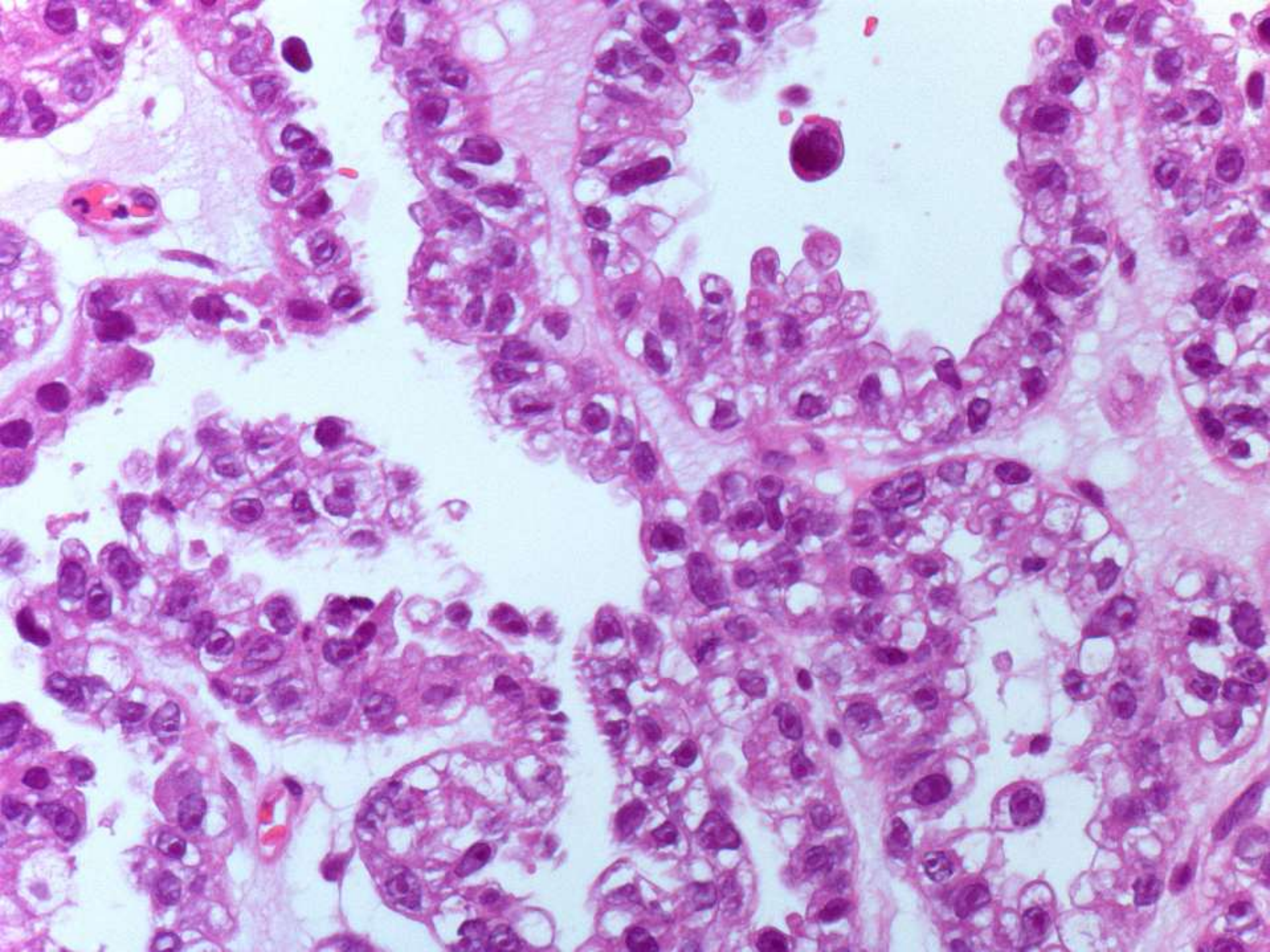


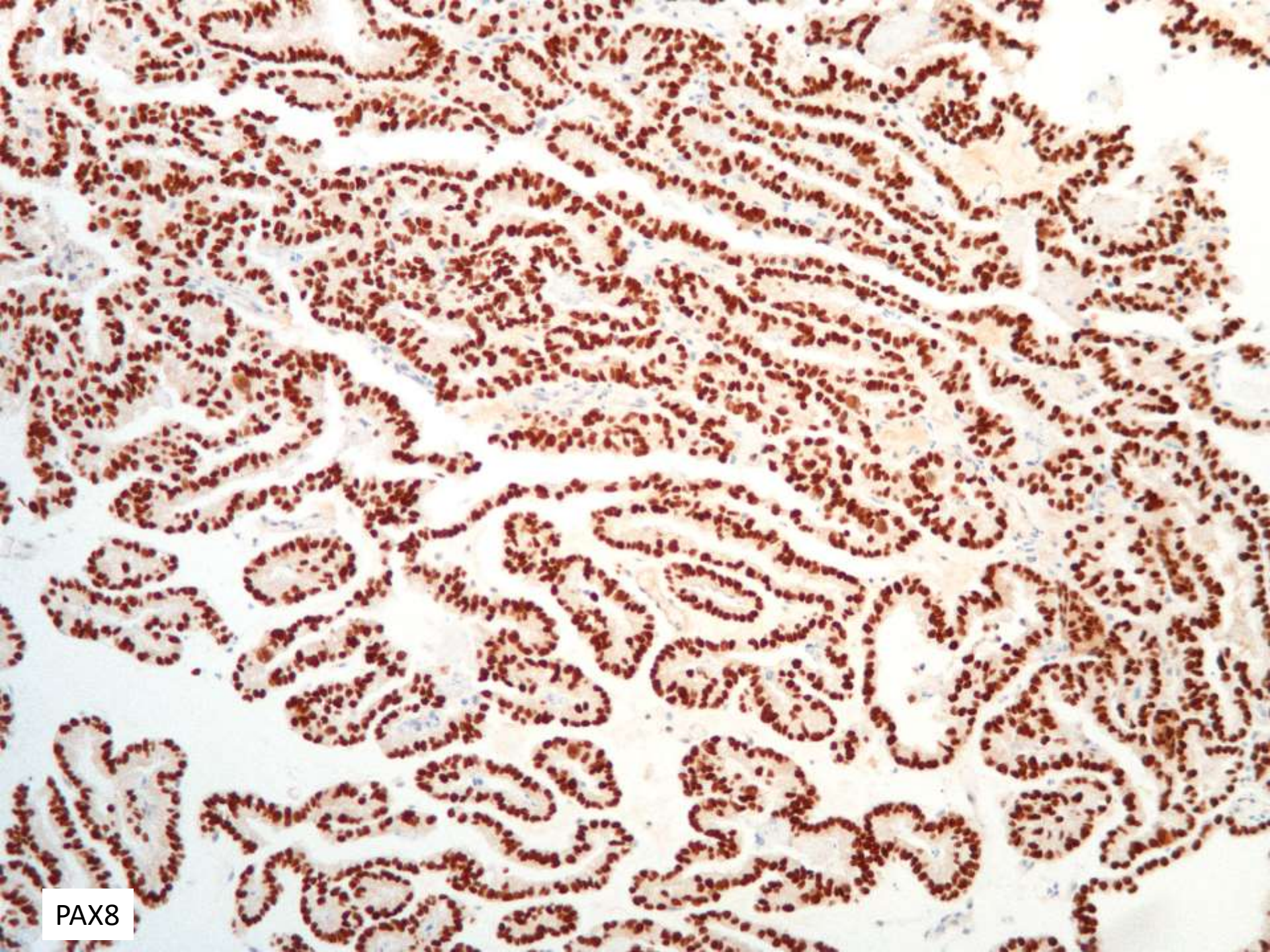




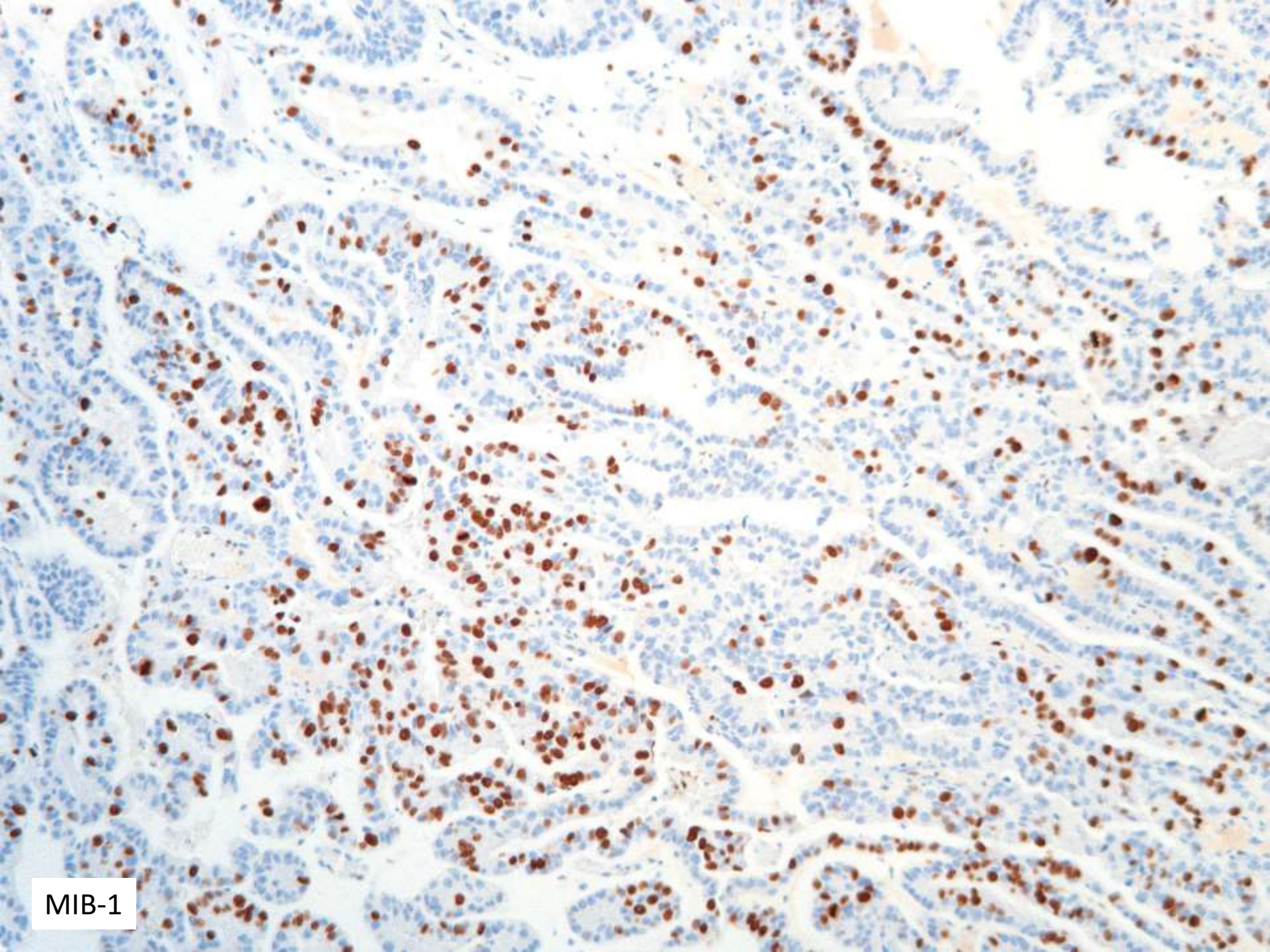




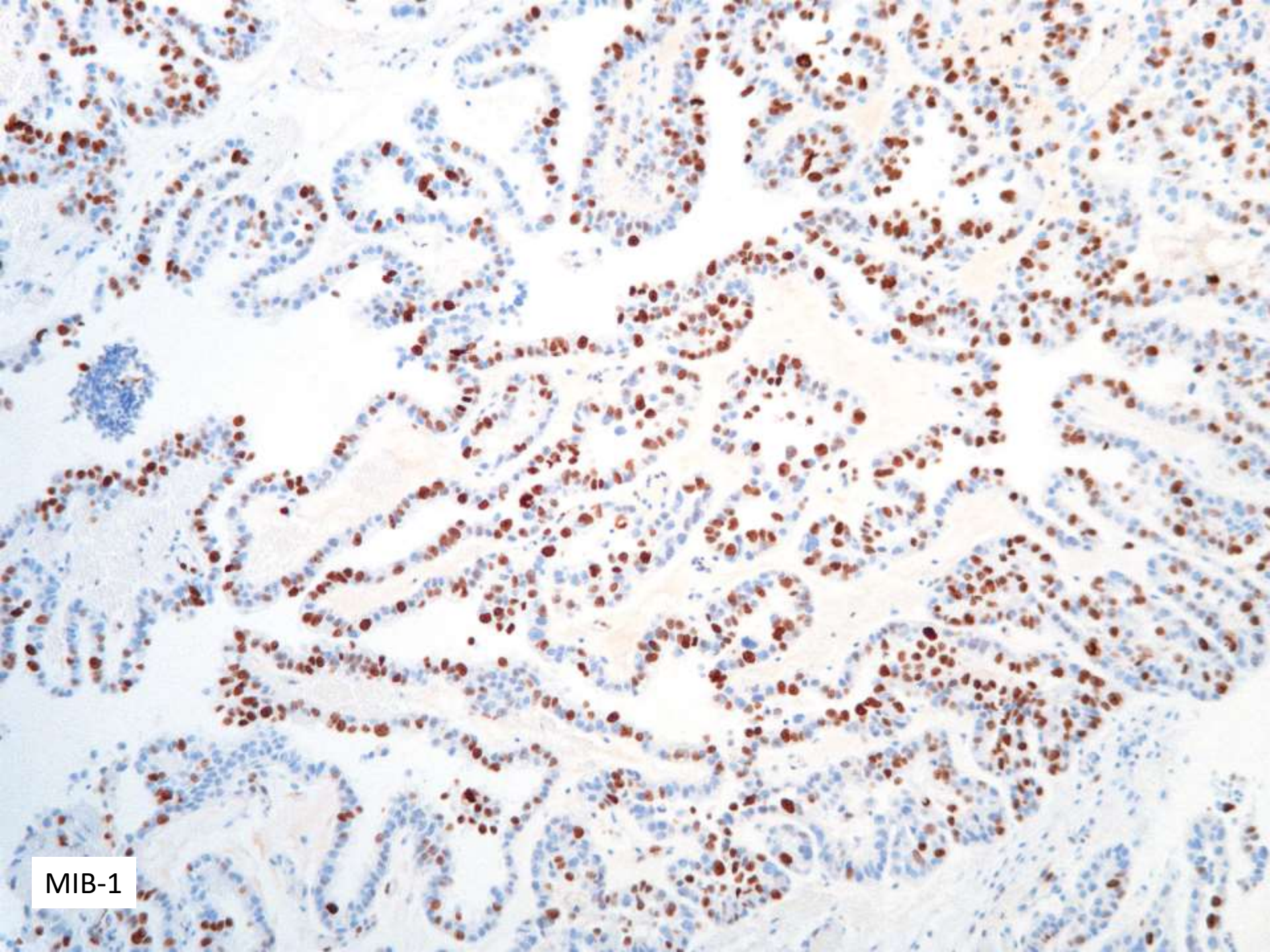




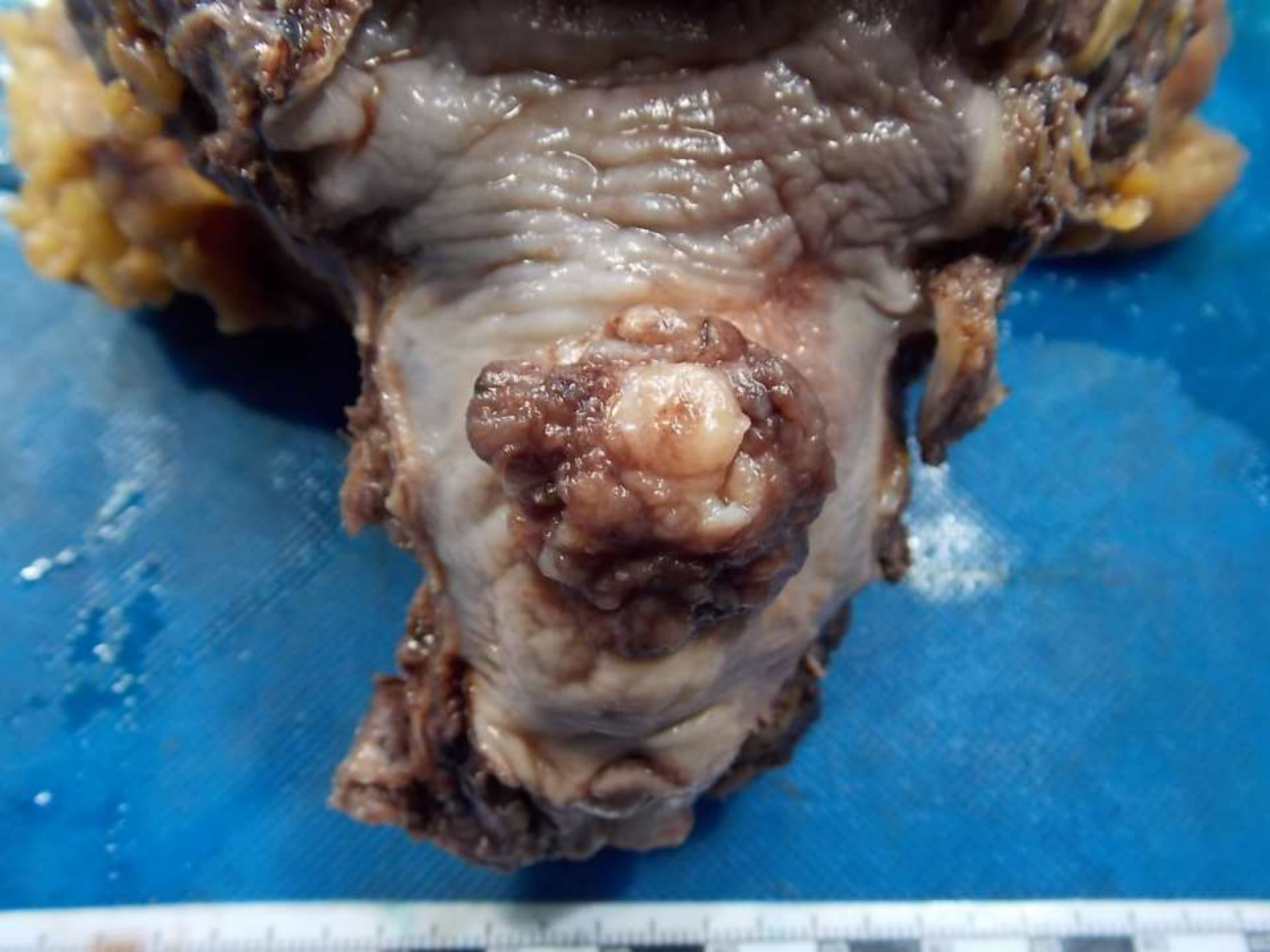PAX8

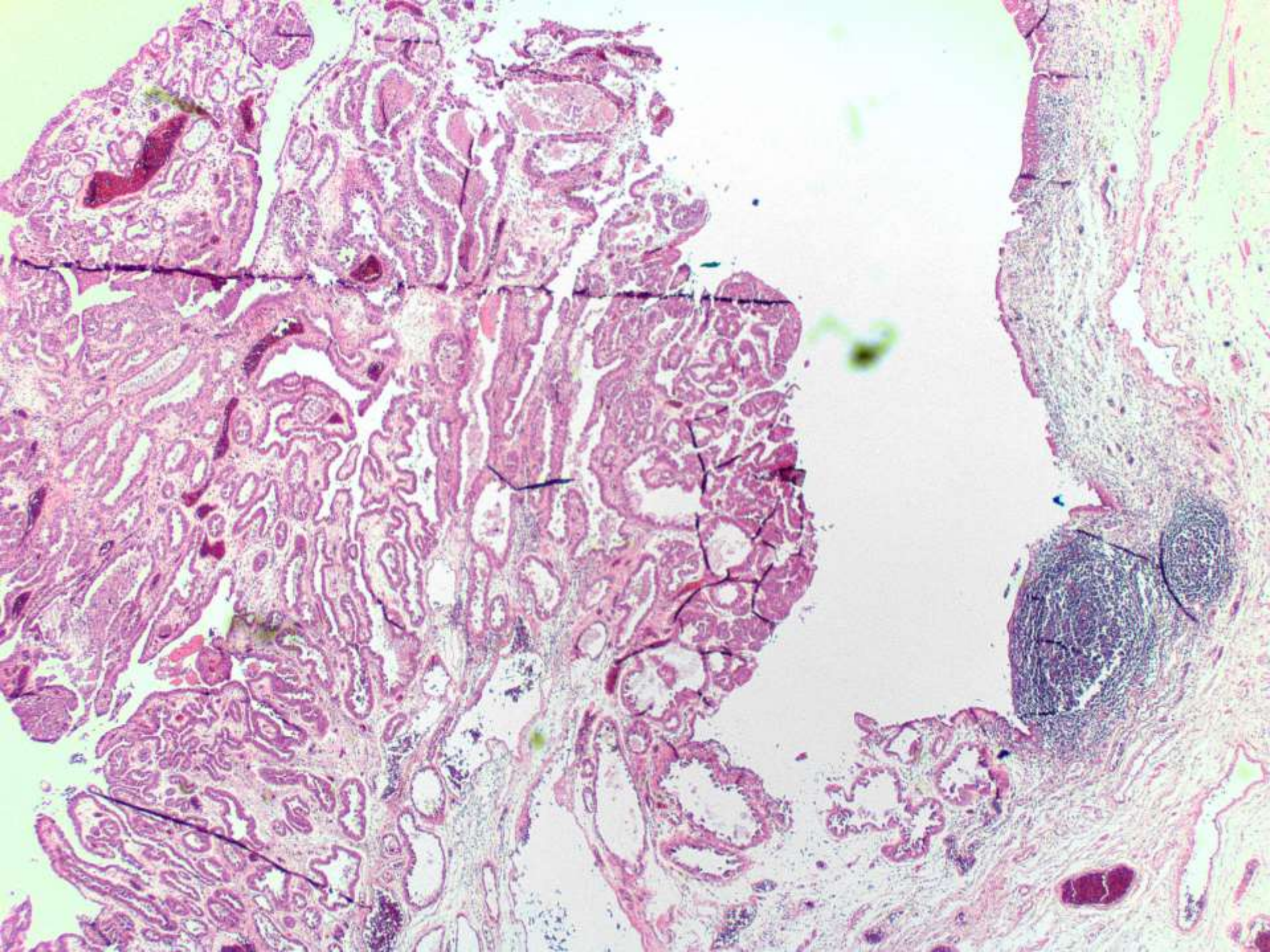


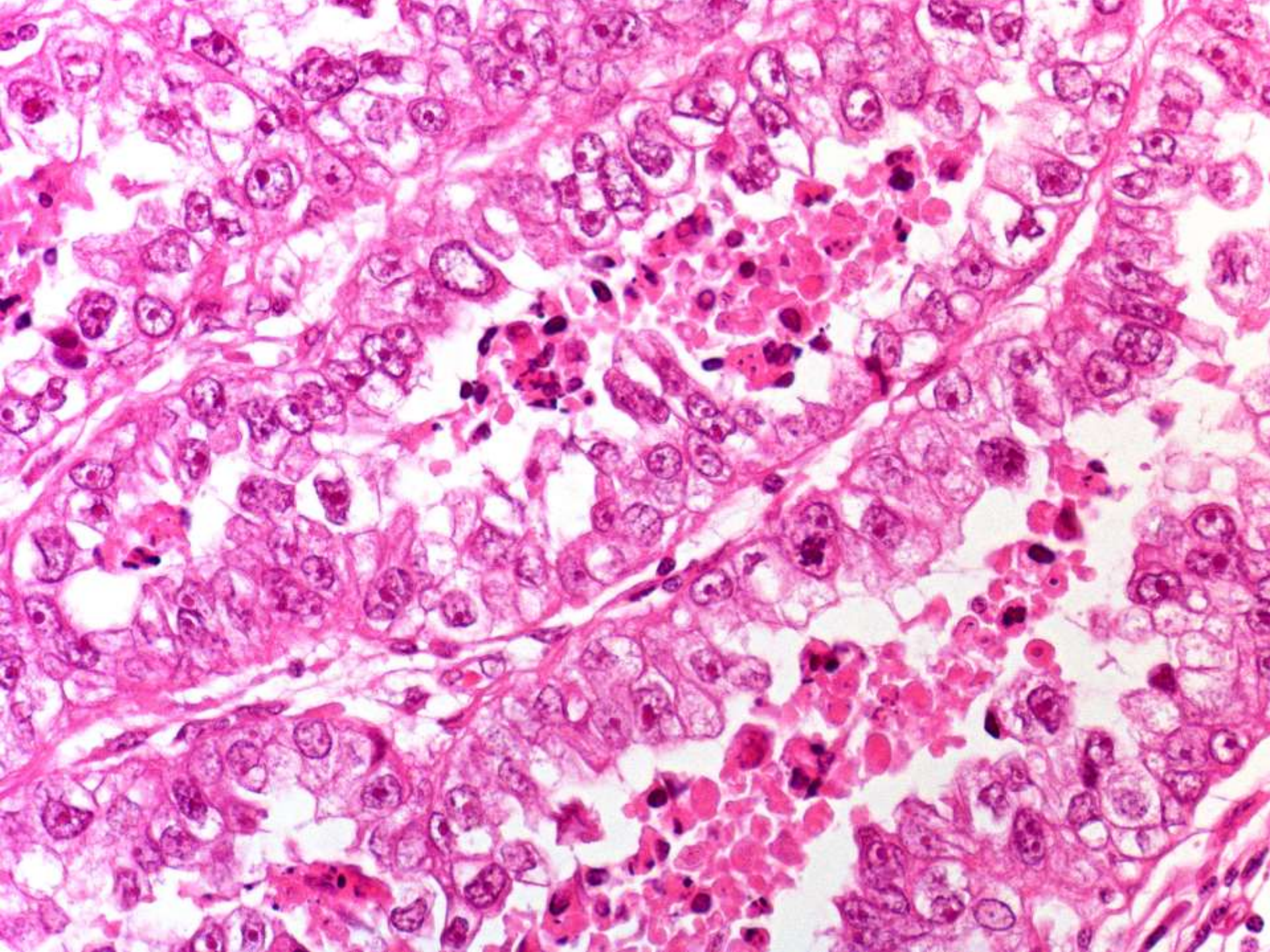
MIB-1

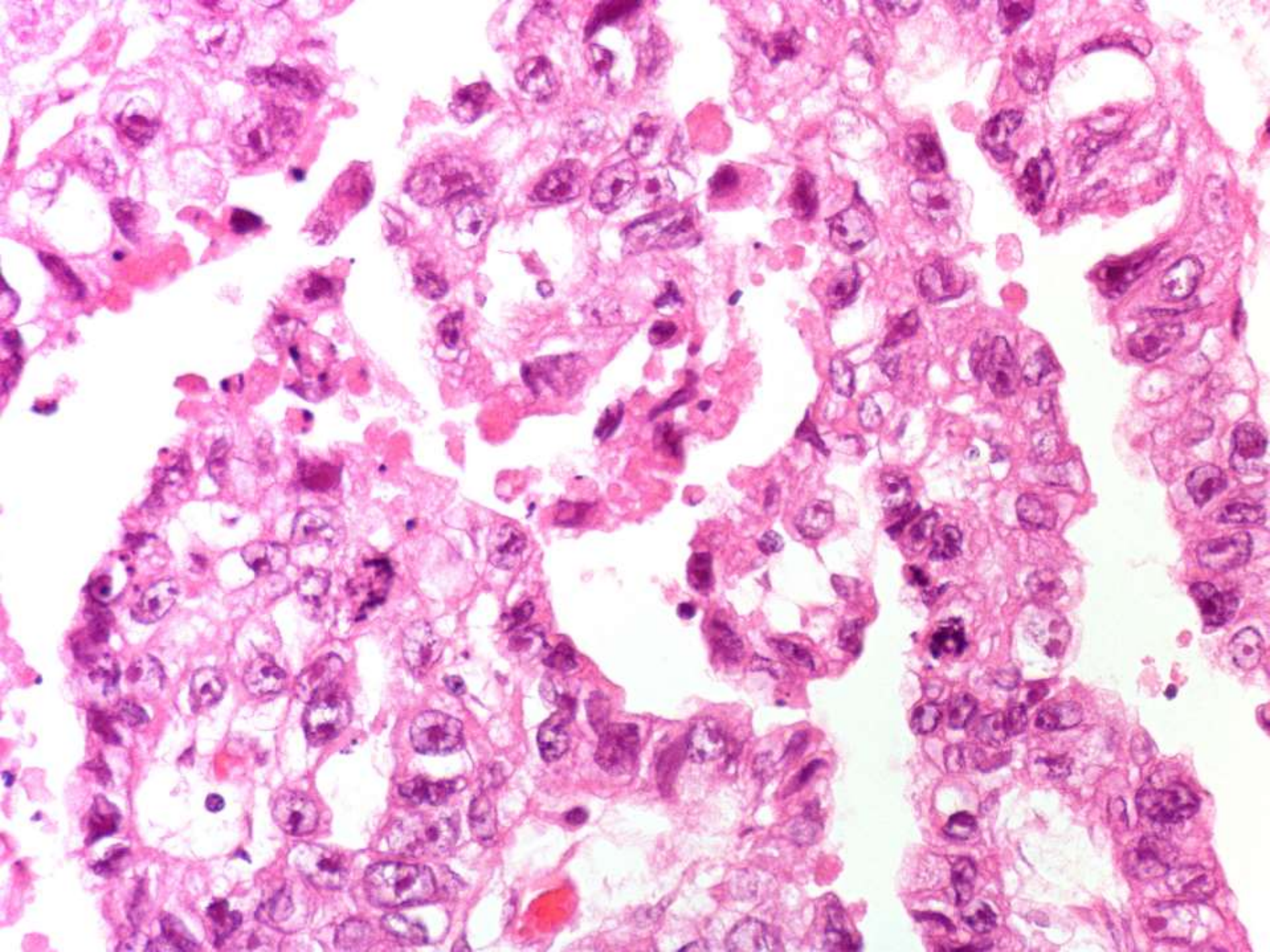


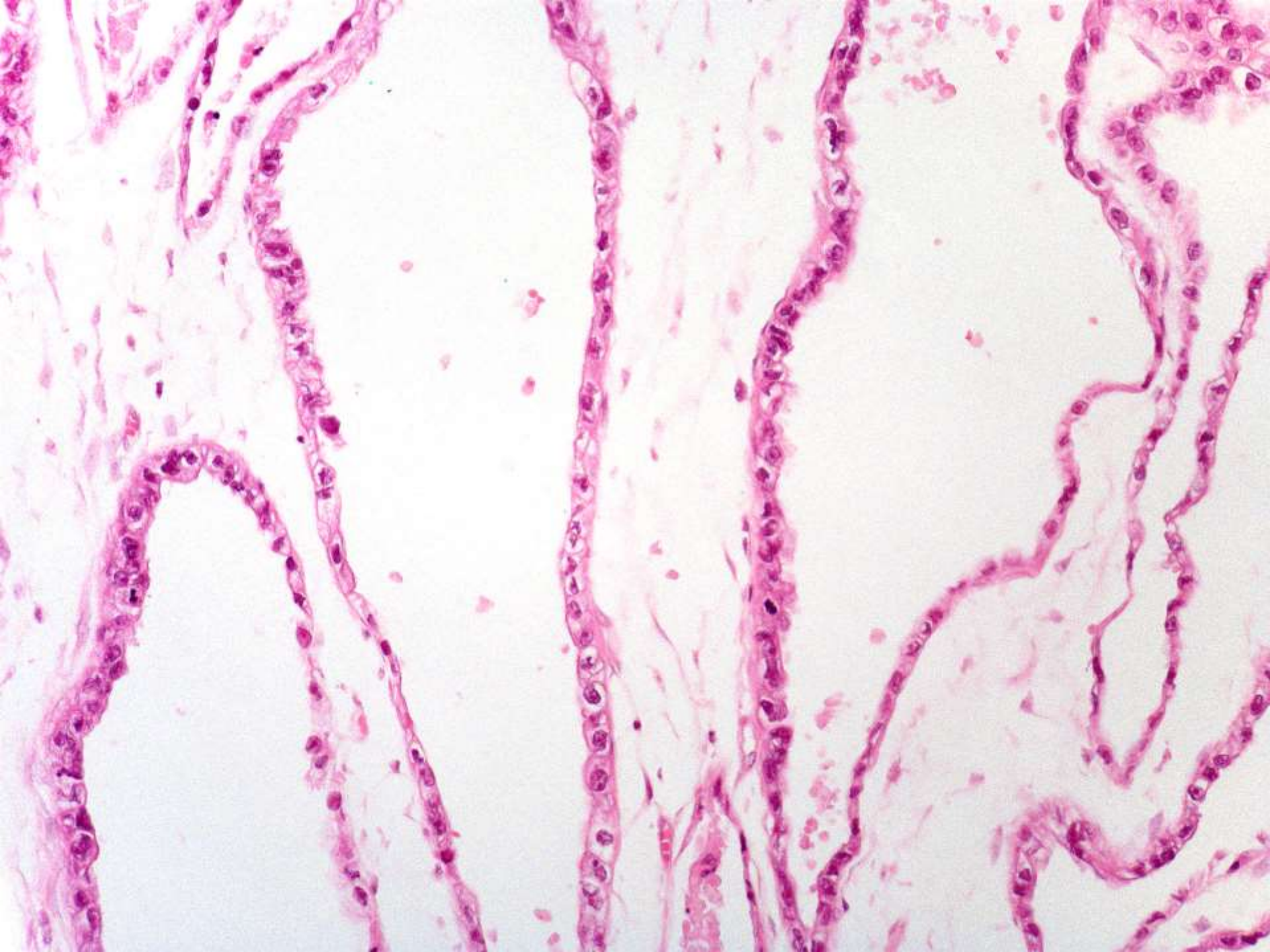
MIB-1

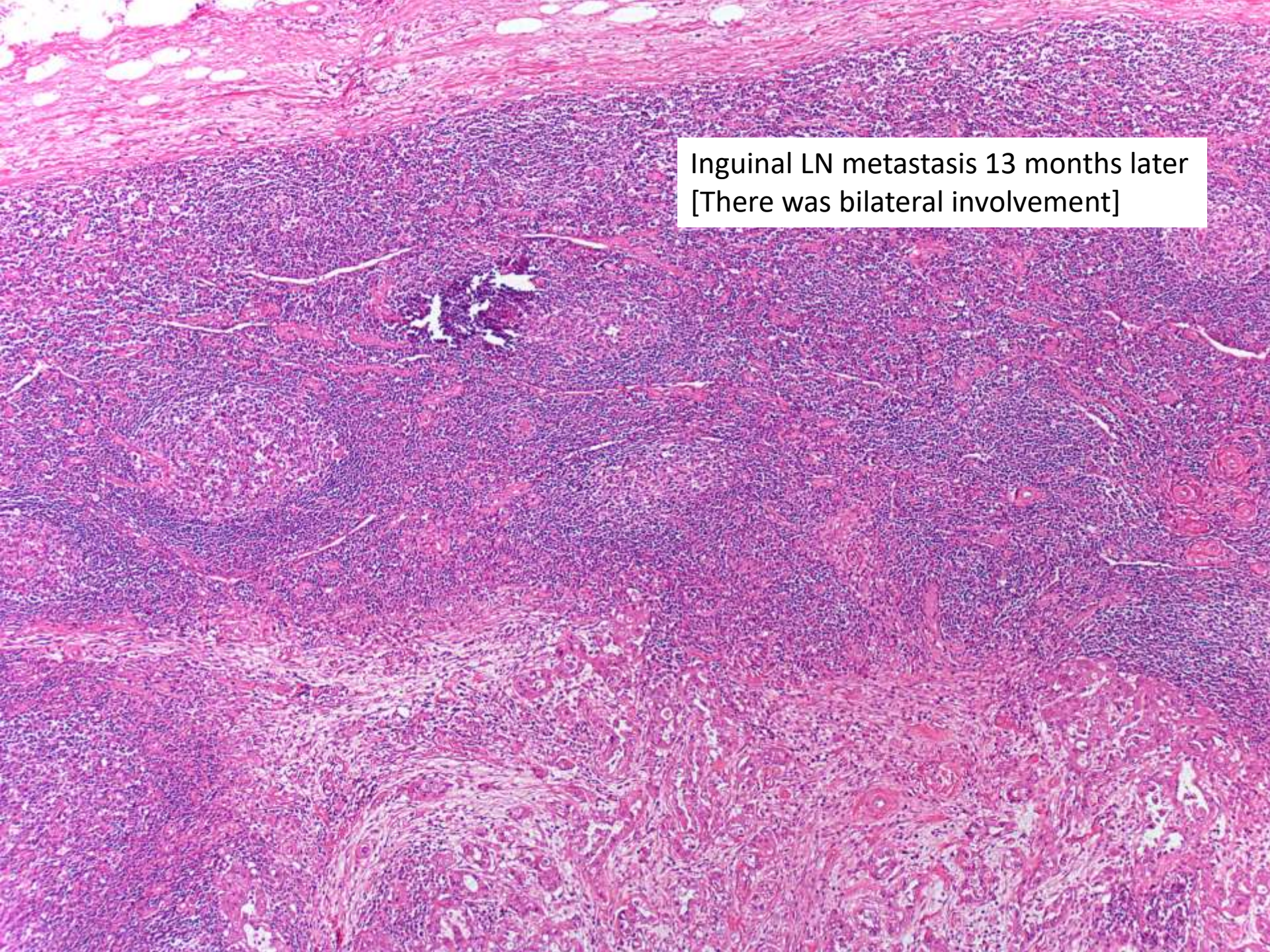




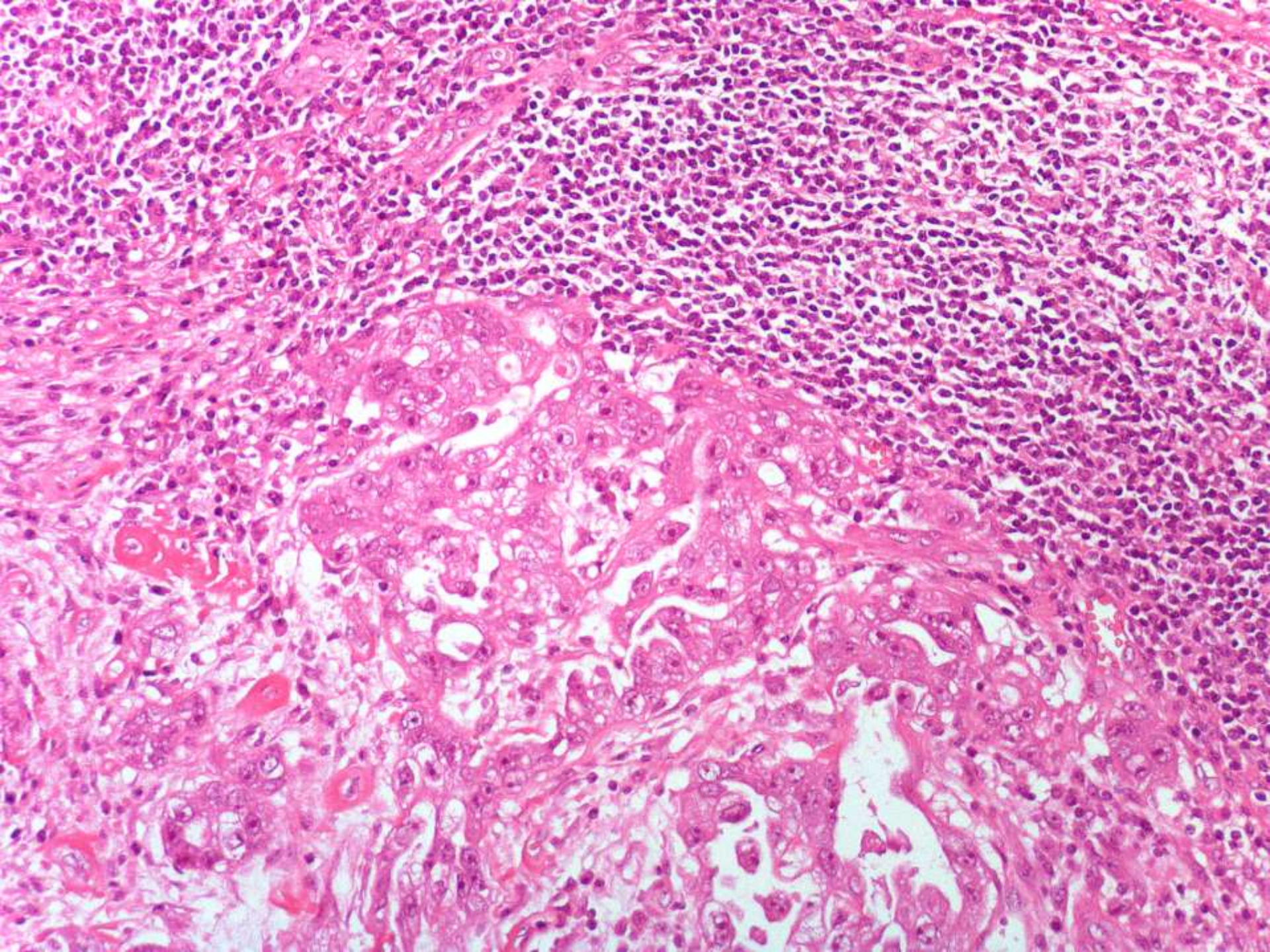


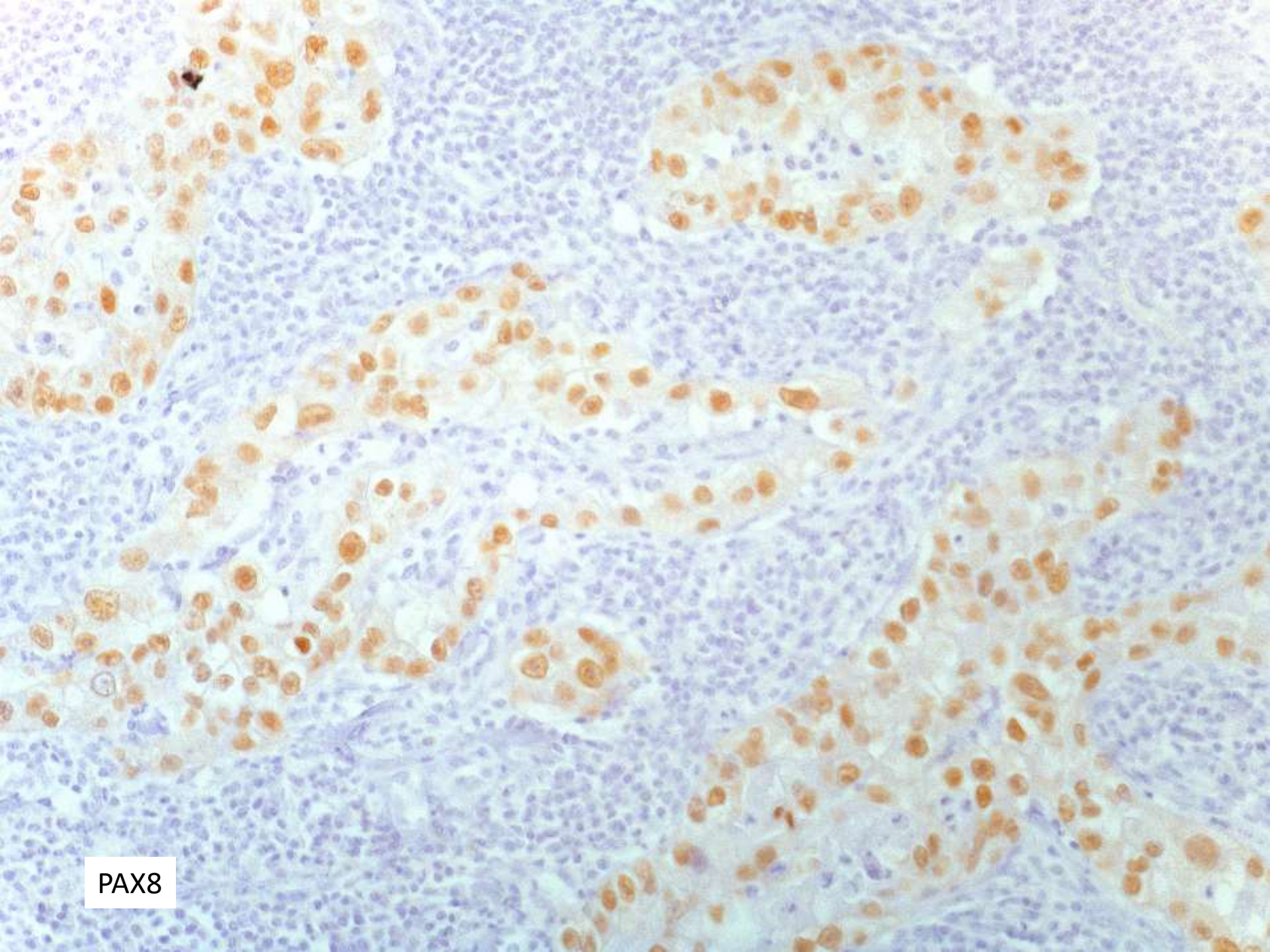




A low-magnification histological slide of an inguinal lymph node stained with hematoxylin and eosin (H&E). The image shows a dense population of cells, with a prominent area of metastatic tumor cells. These cells are arranged in nests and cords, characteristic of a carcinoma. The surrounding lymphoid tissue is compressed and displaced by the tumor. The overall appearance is that of a lymph node heavily infiltrated by metastatic disease.

Inguinal LN metastasis 13 months later  
[There was bilateral involvement]





PAX8

# Spindle cell lesions of bladder

A variety of soft tissue type spindle cells lesions can occur in the bladder. However, the most common scenario is:

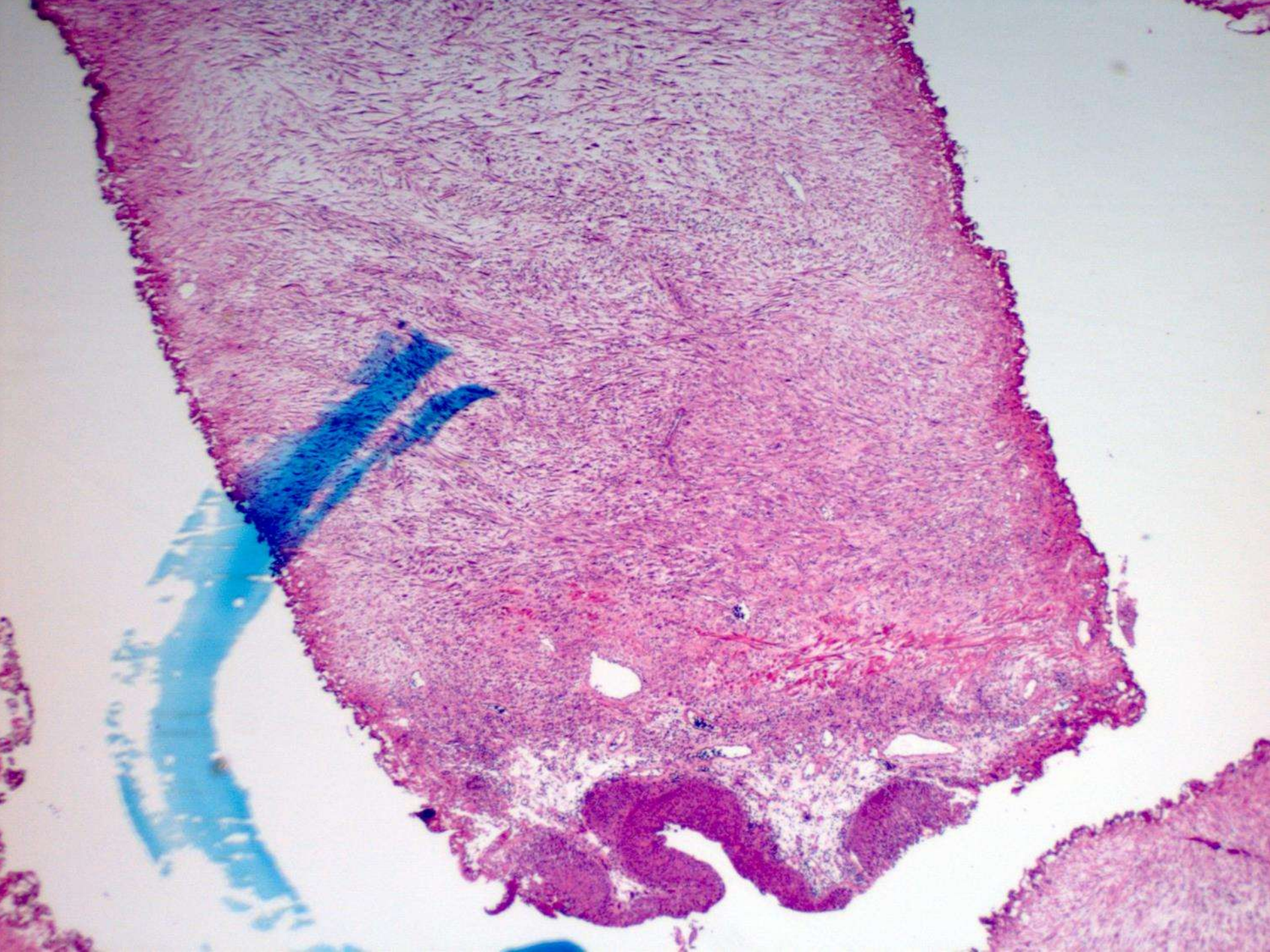
- Sarcomatoid carcinoma
  - Sarcoma e.g. leiomyosarcoma

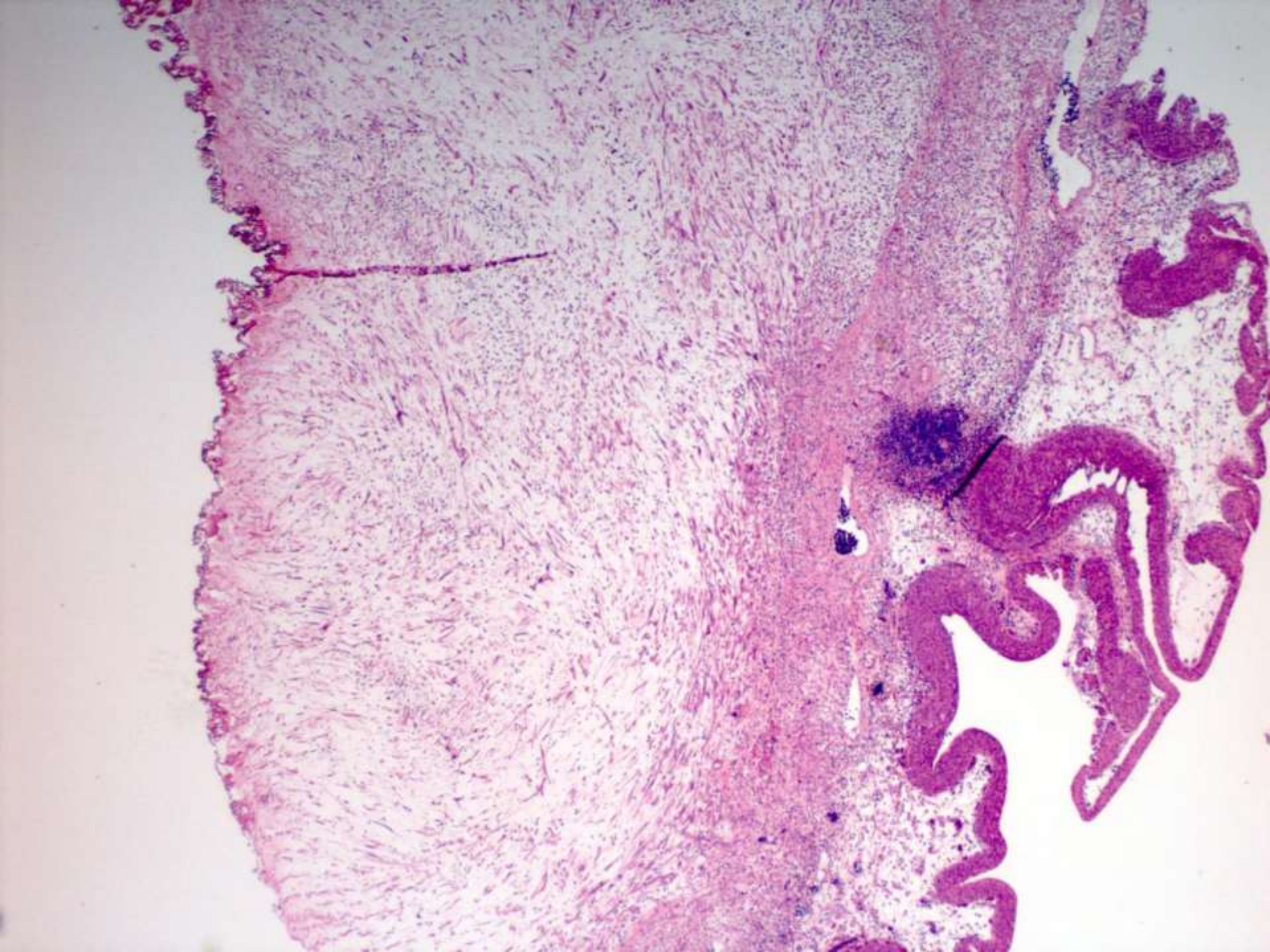
versus

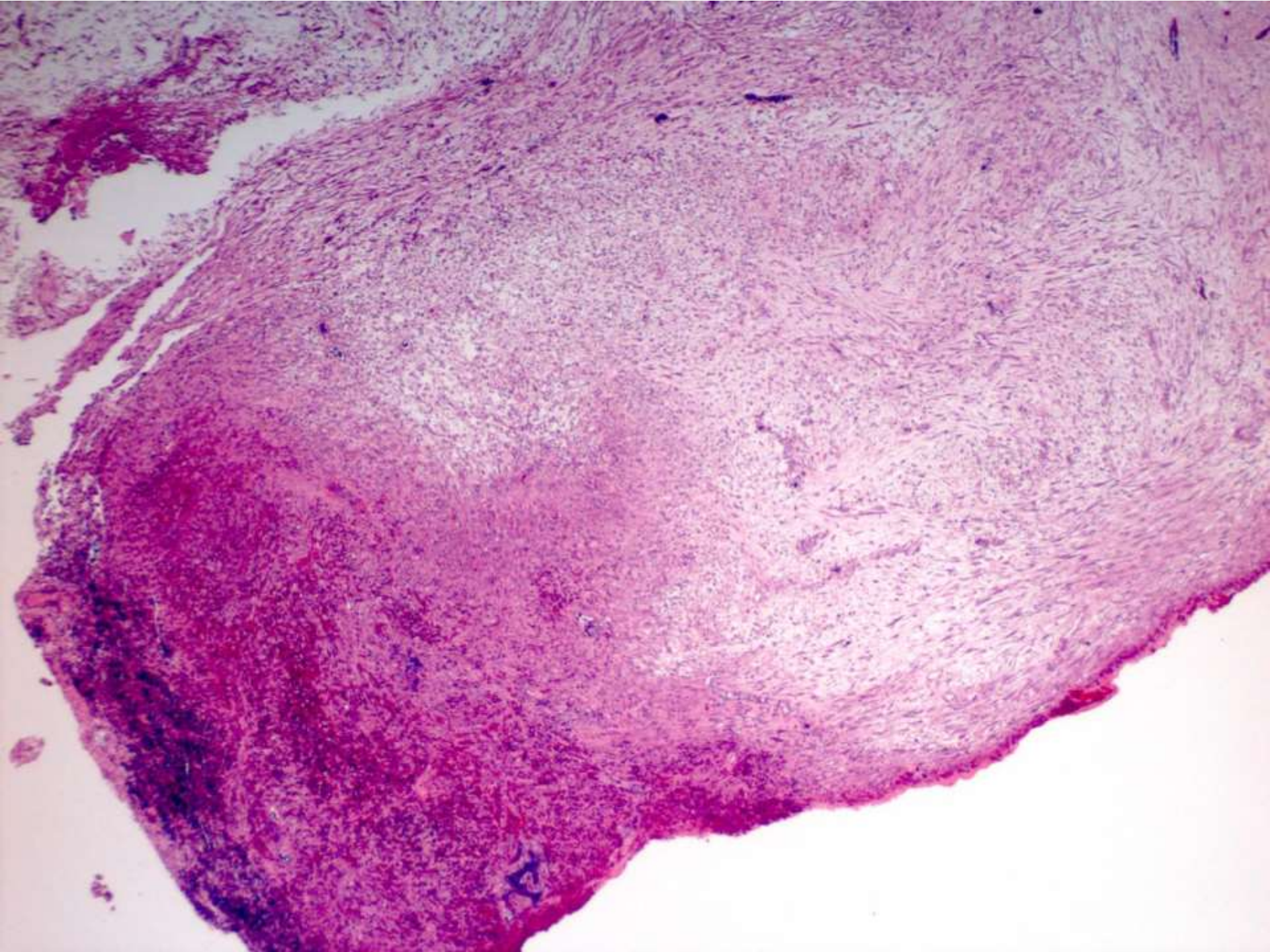
- Inflammatory myofibroblastic tumour (IMT)/pseudosarcomatous myofibroblastic proliferation

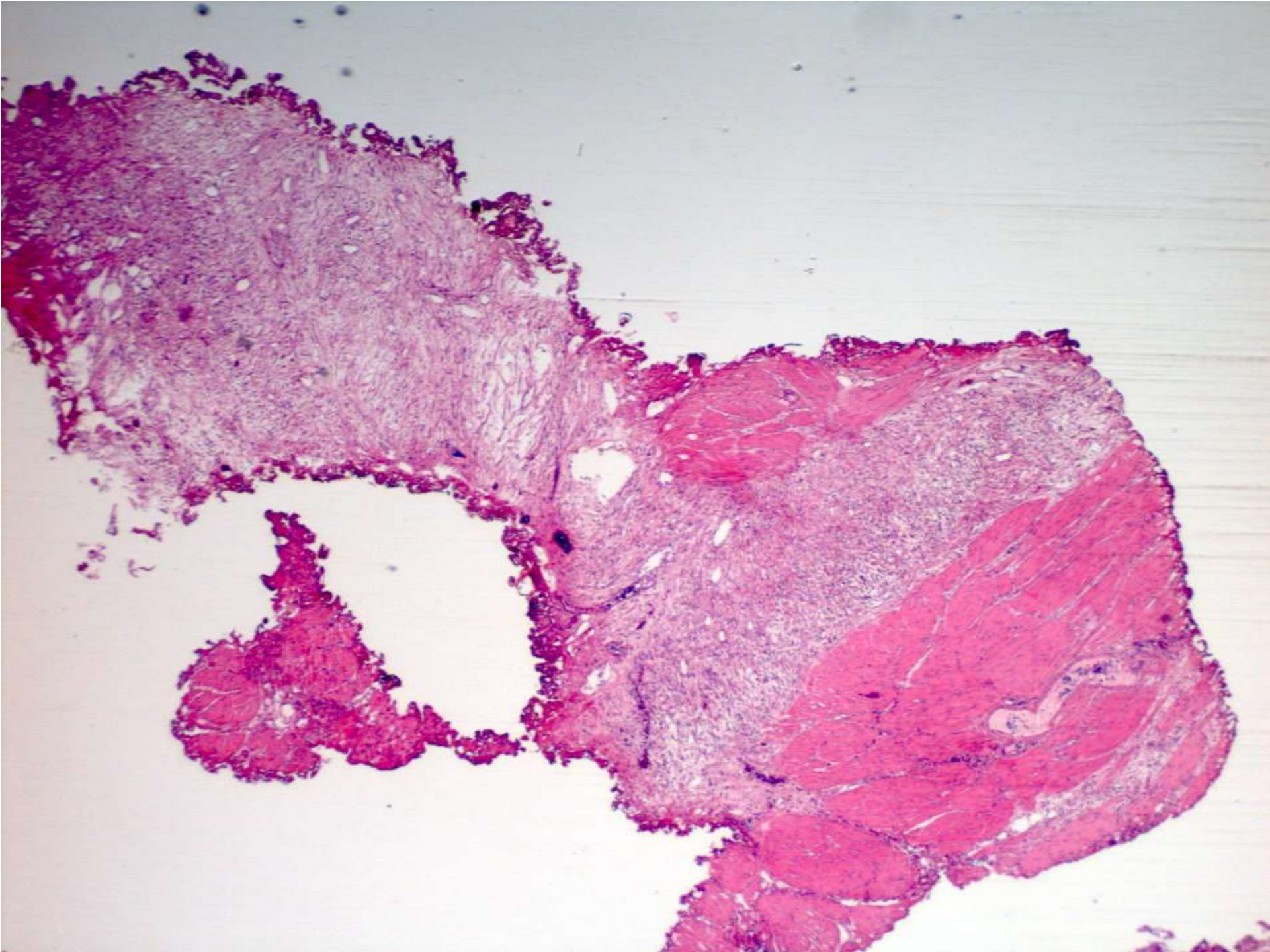
# Case: history

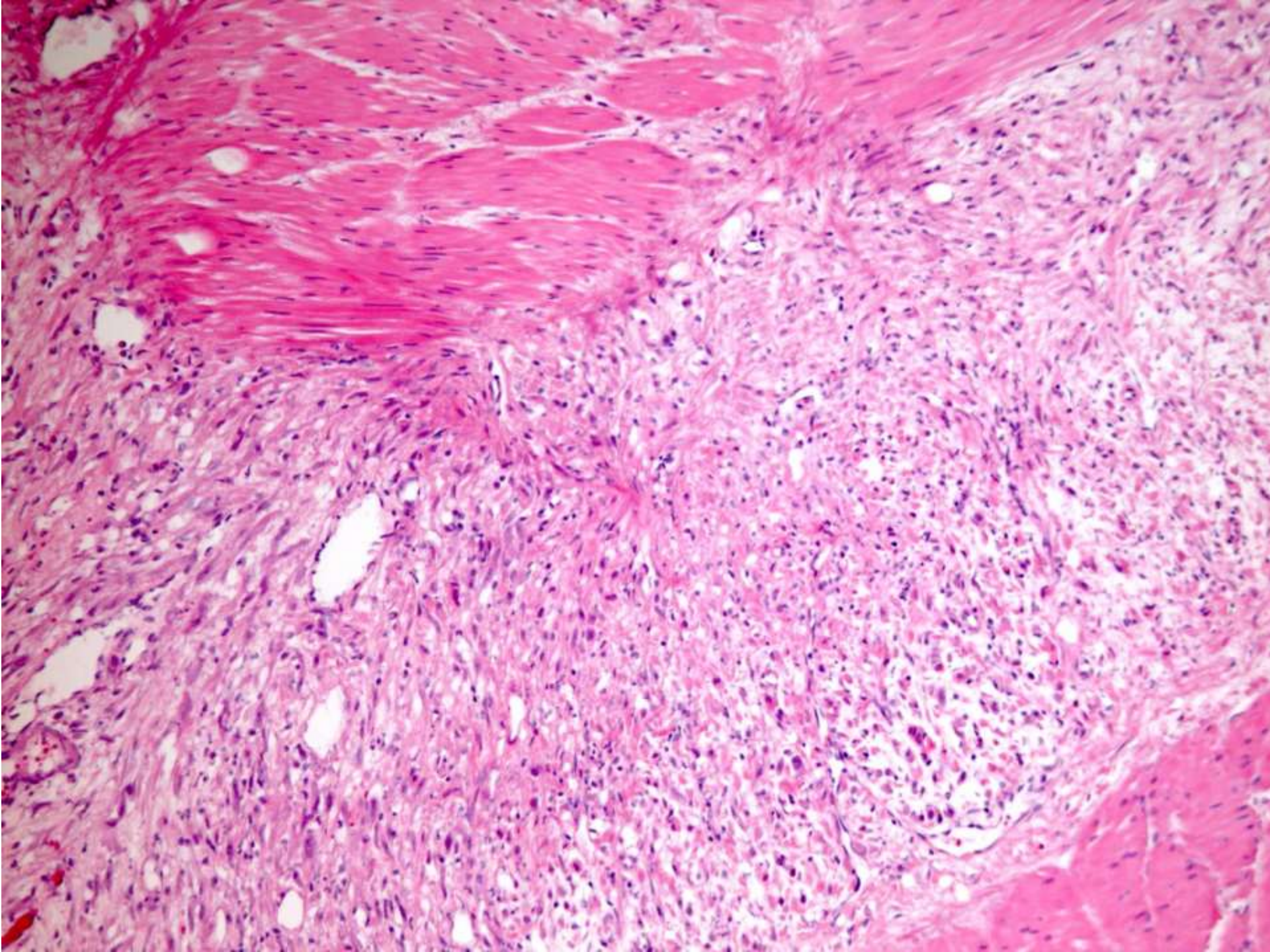
- Female 32 years
- Clinical info: “New bladder lesion appears solid ? Muscle invasive”
- TURBT

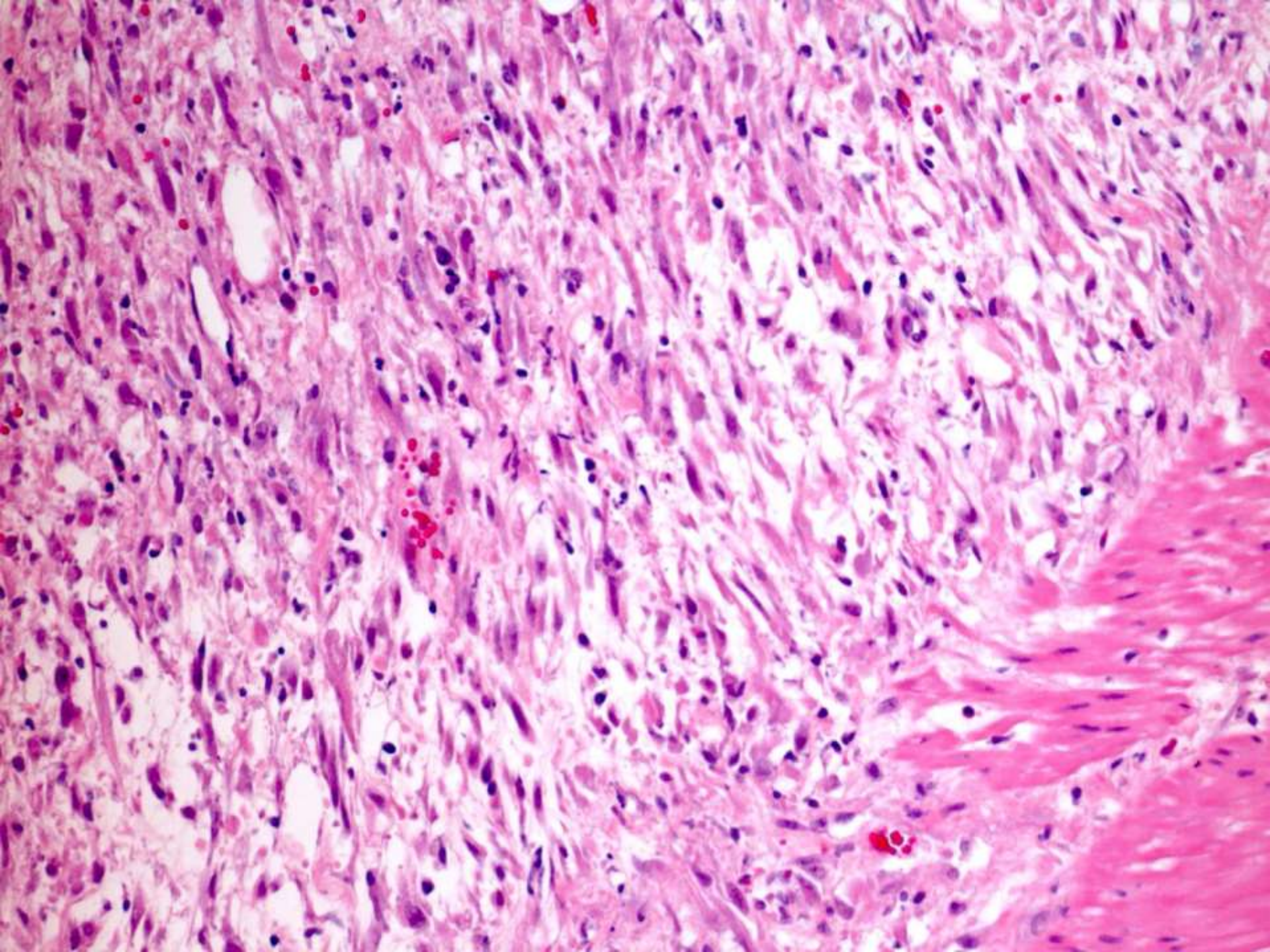


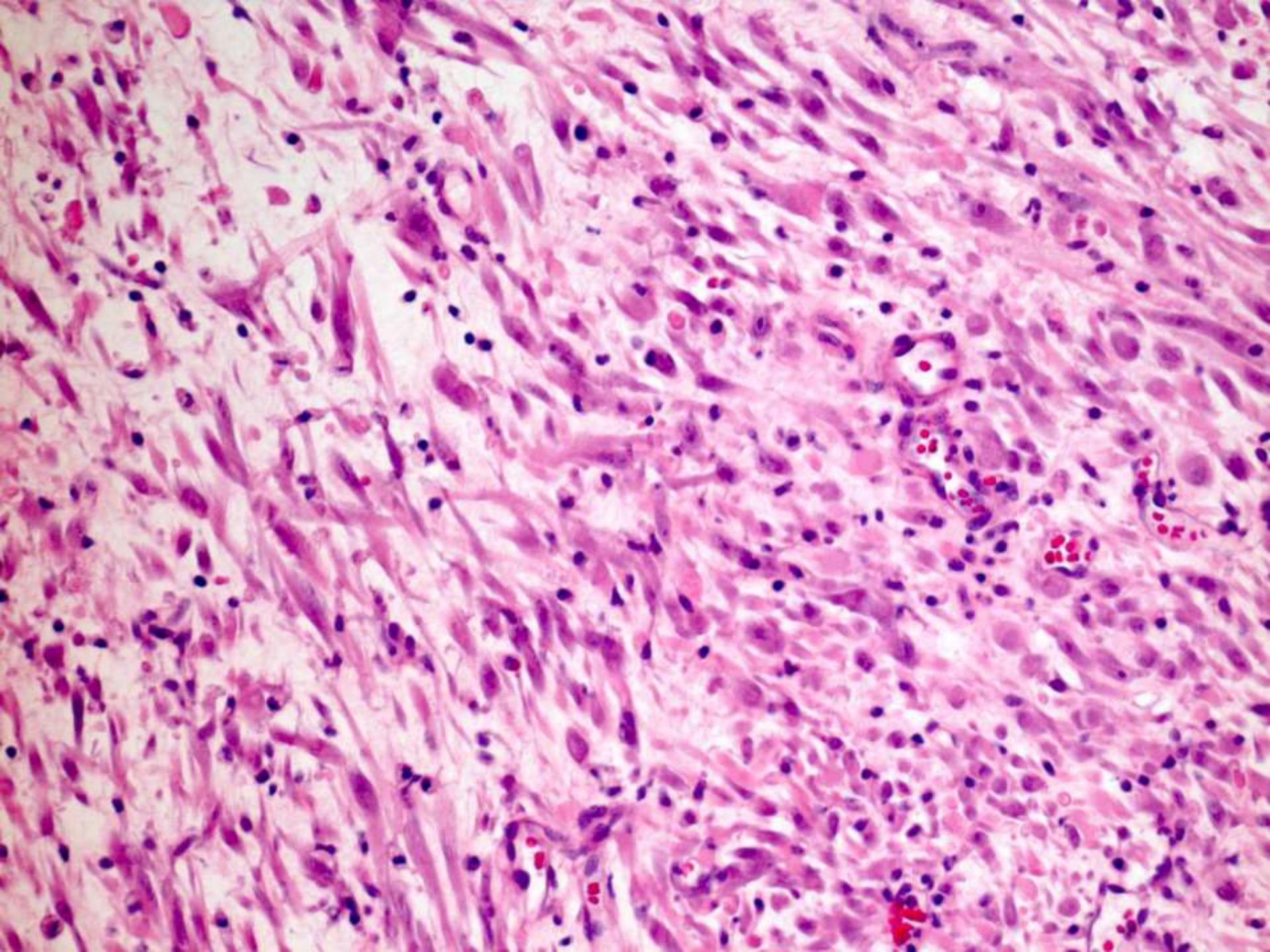


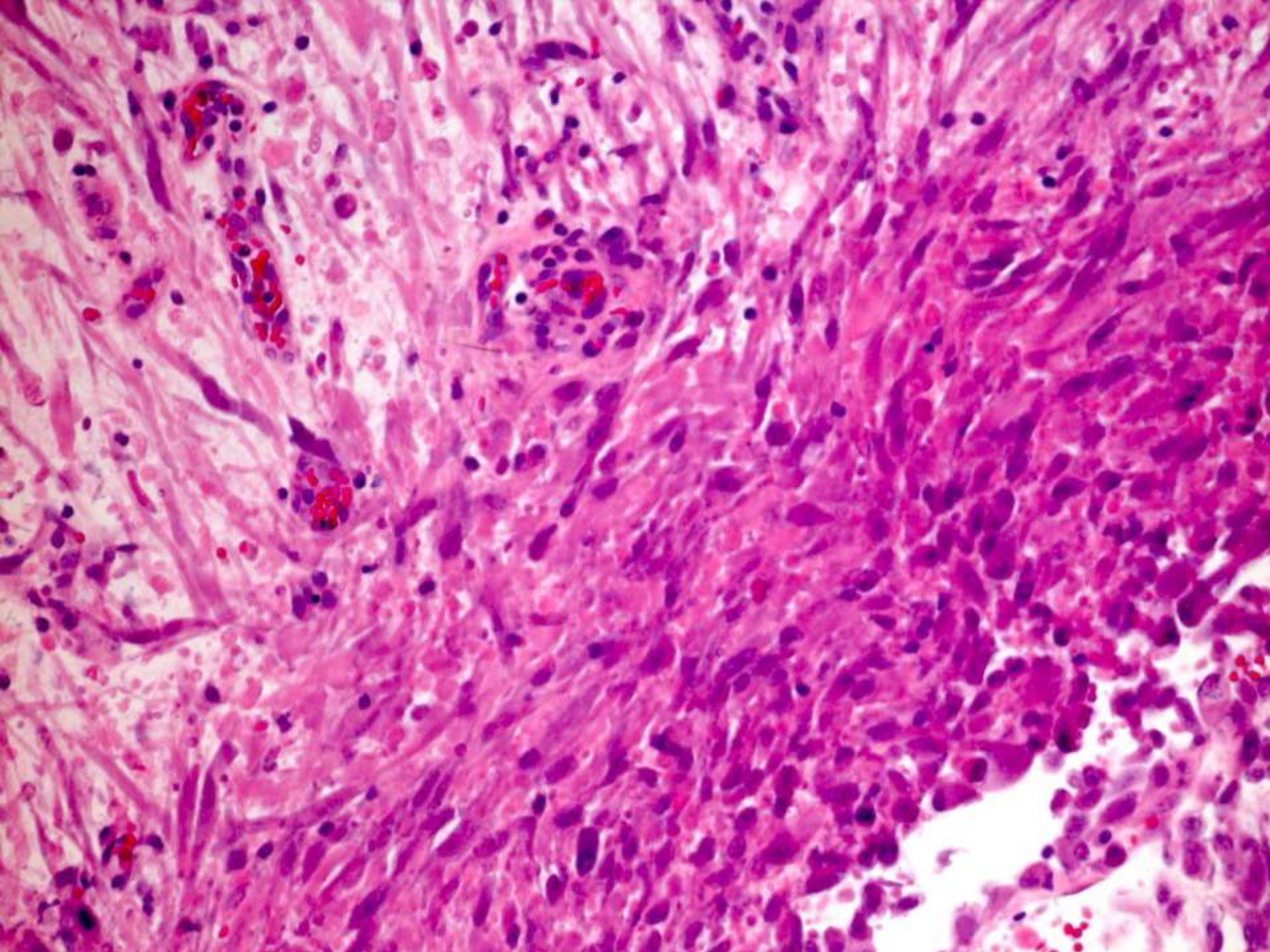


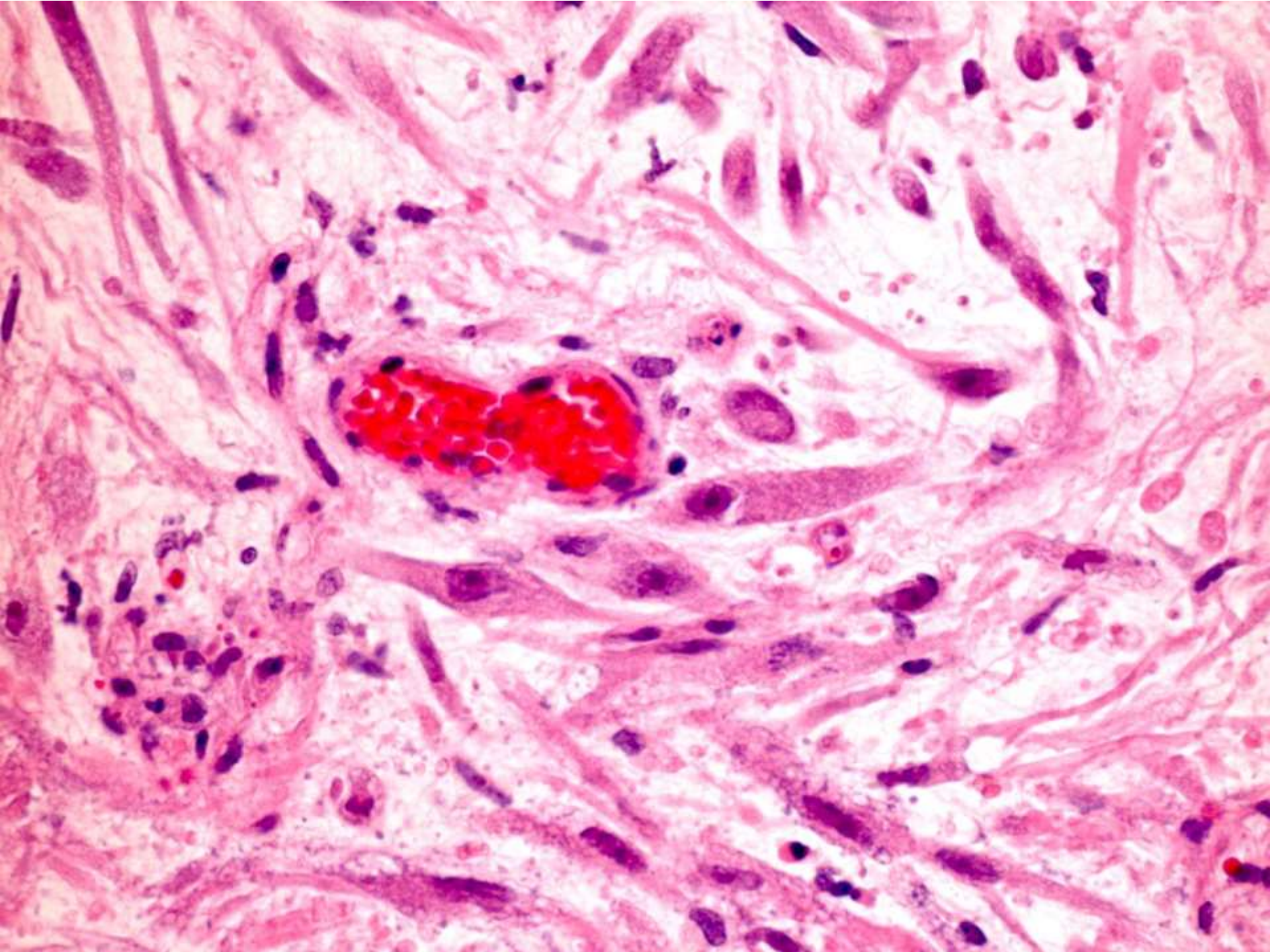


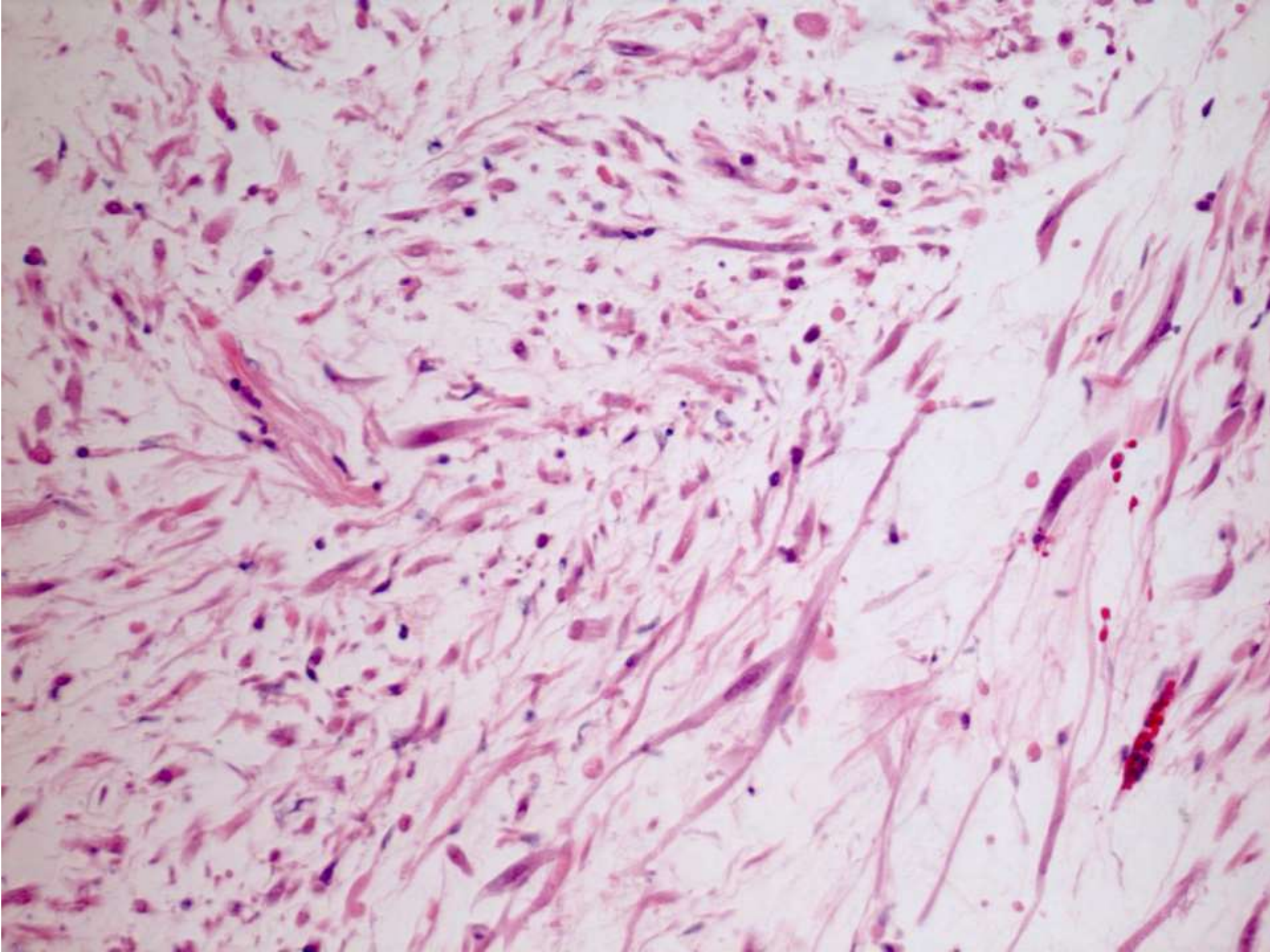


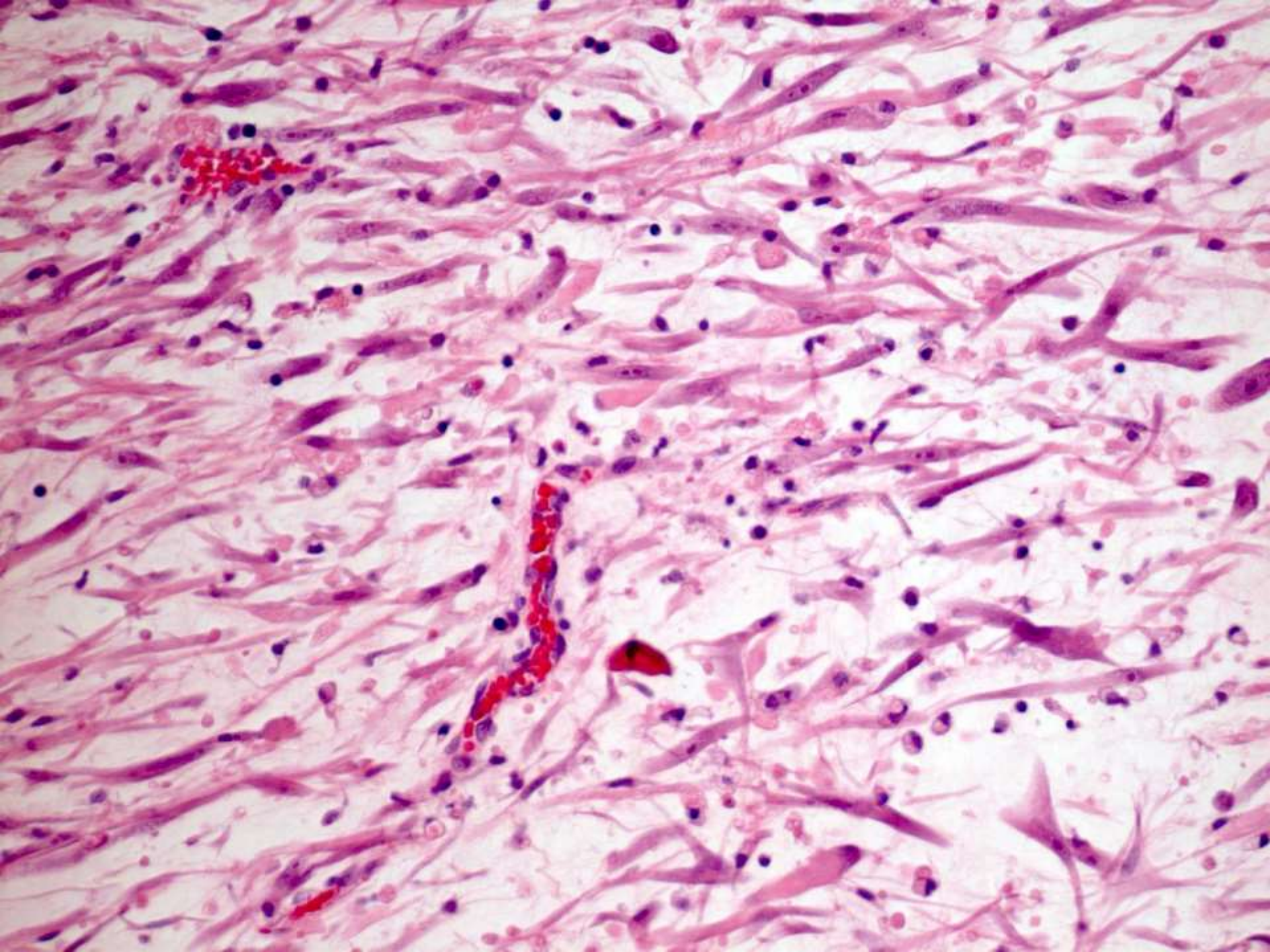


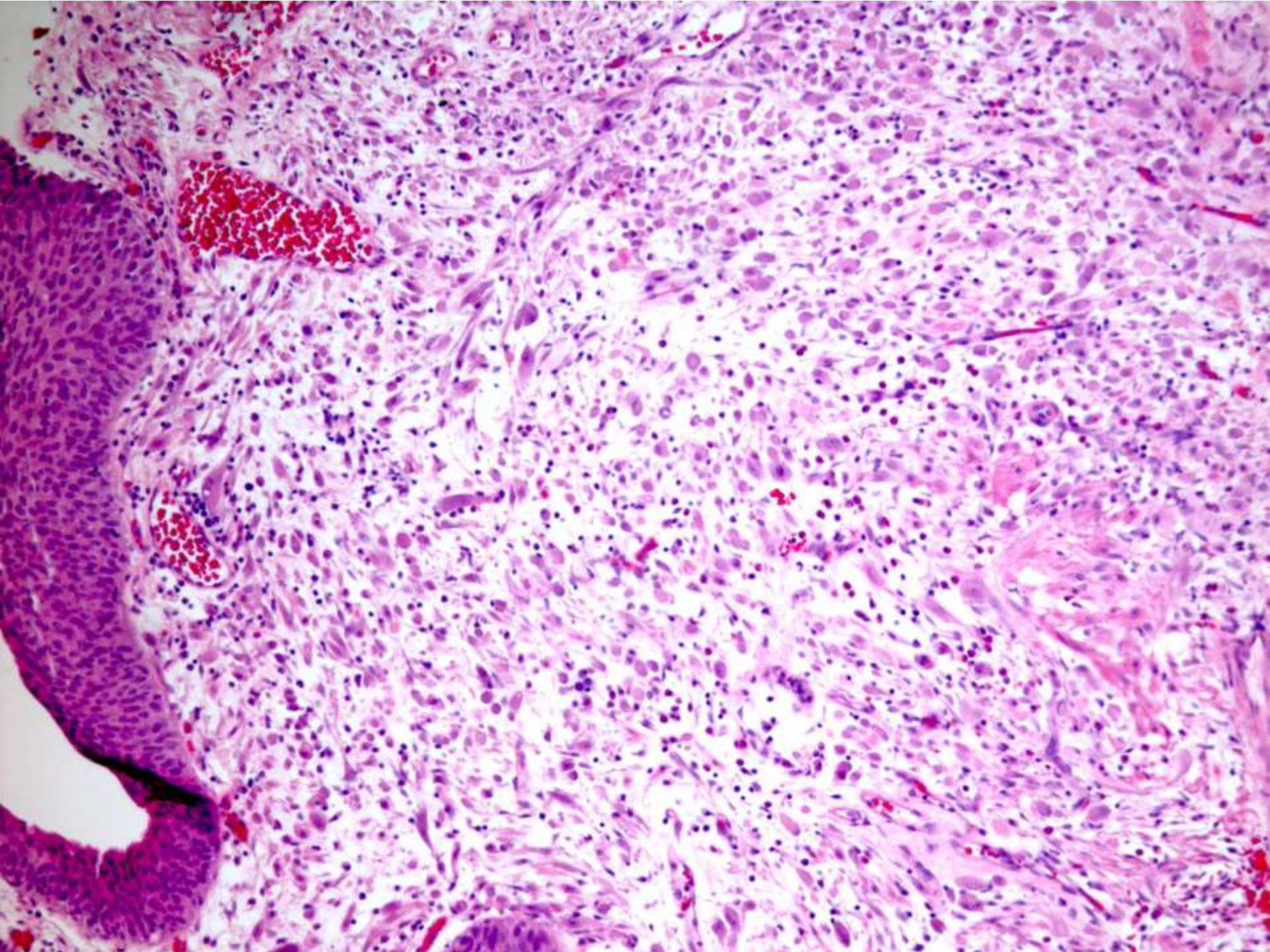


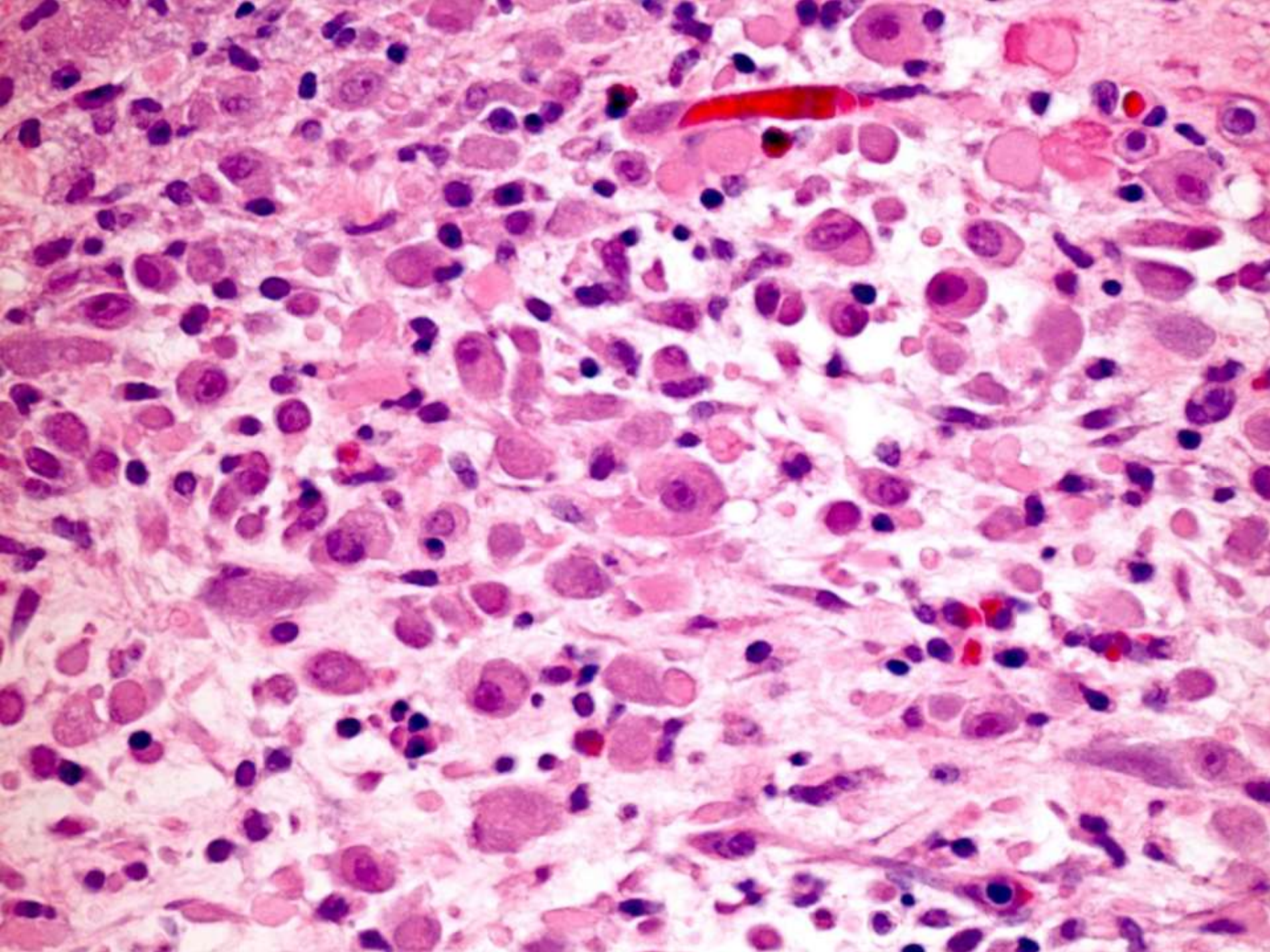


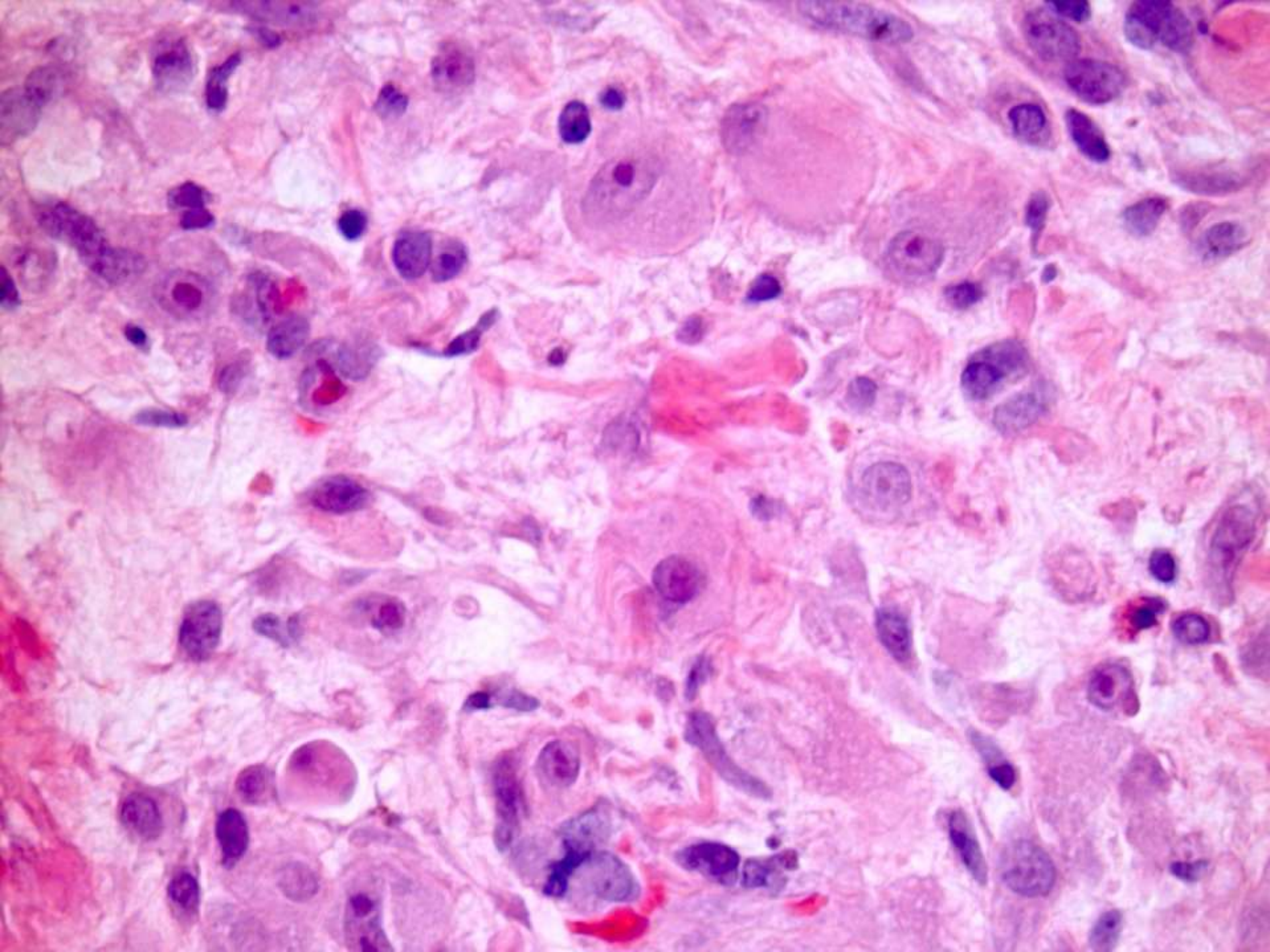


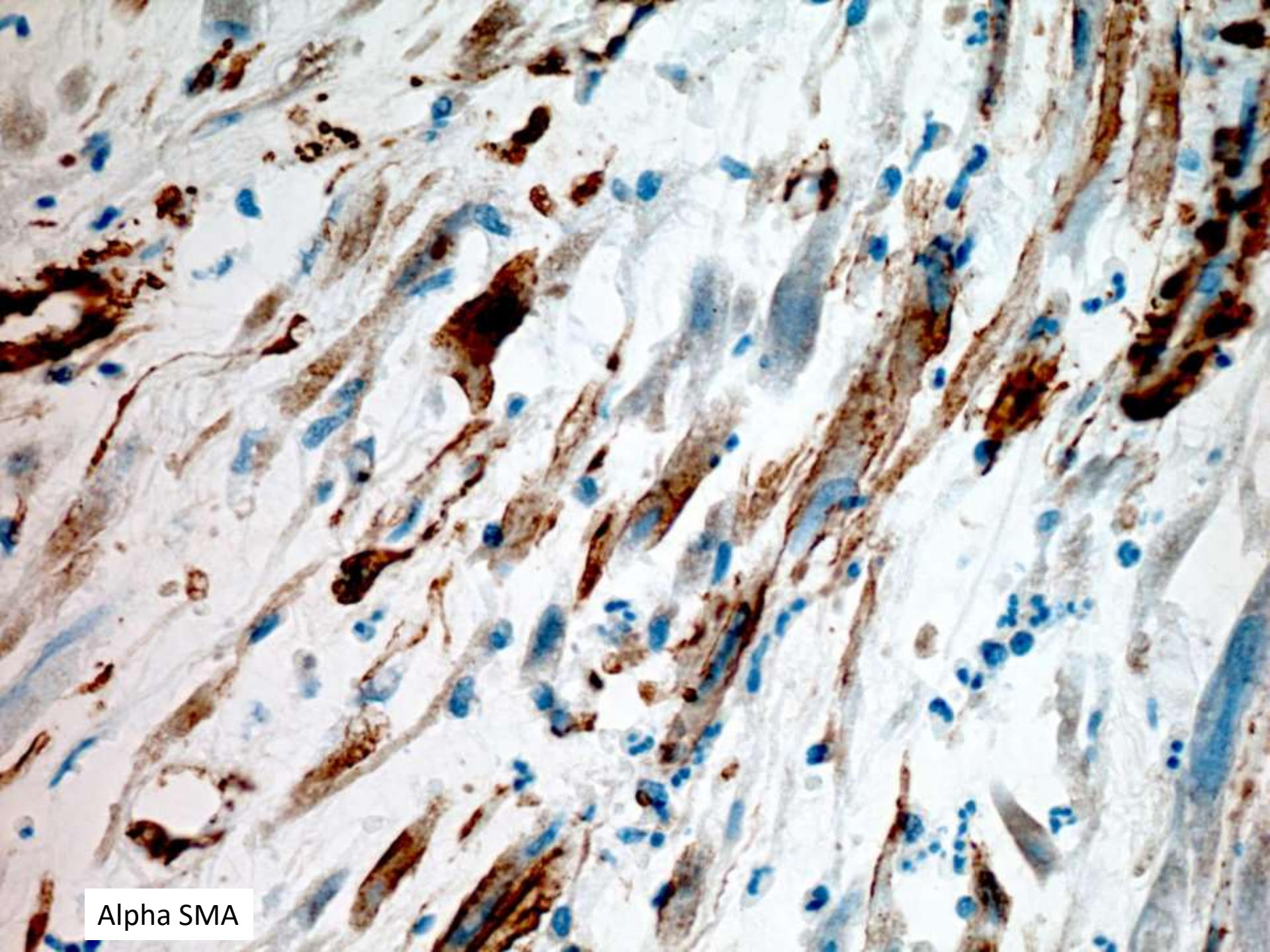




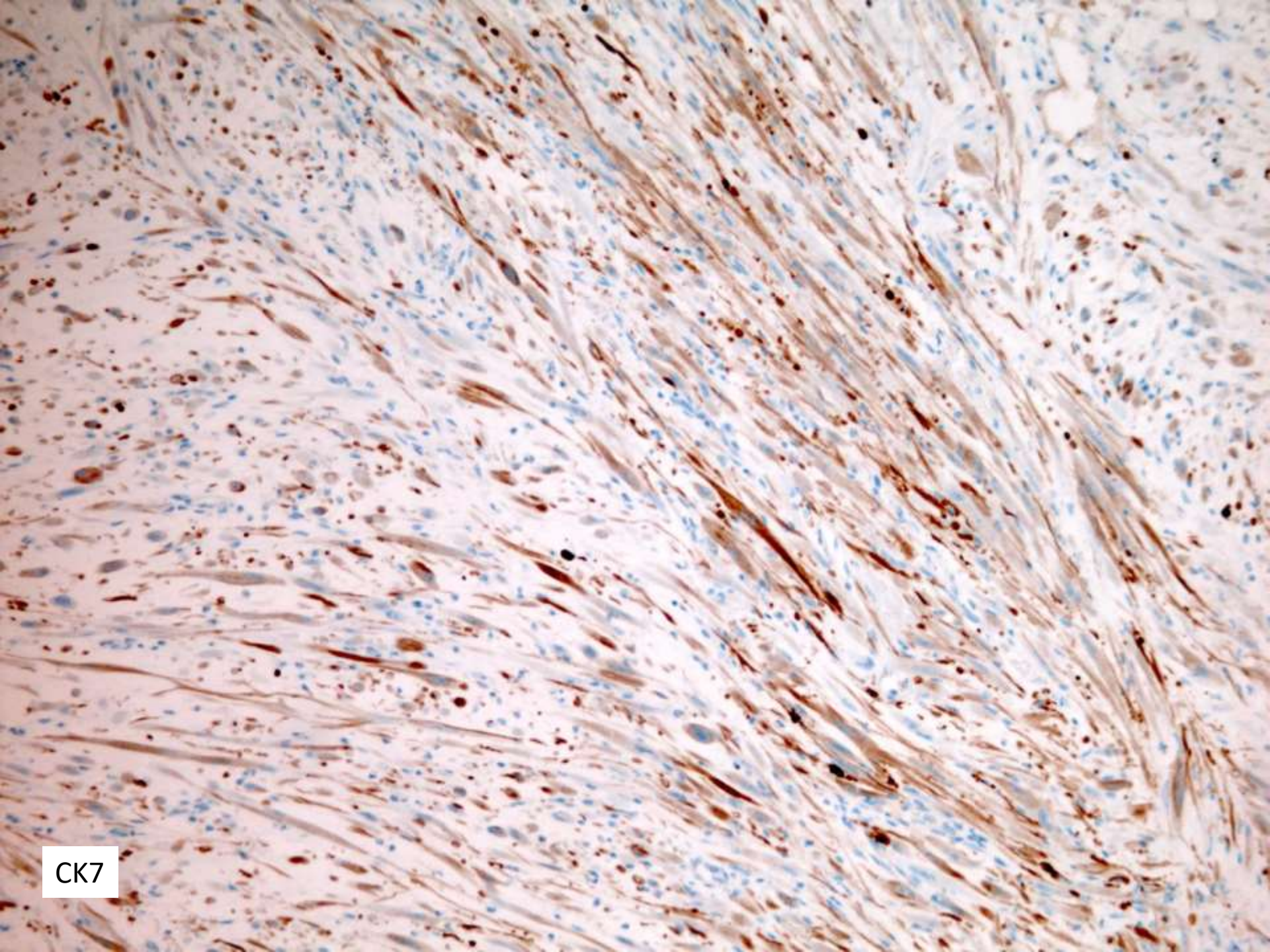




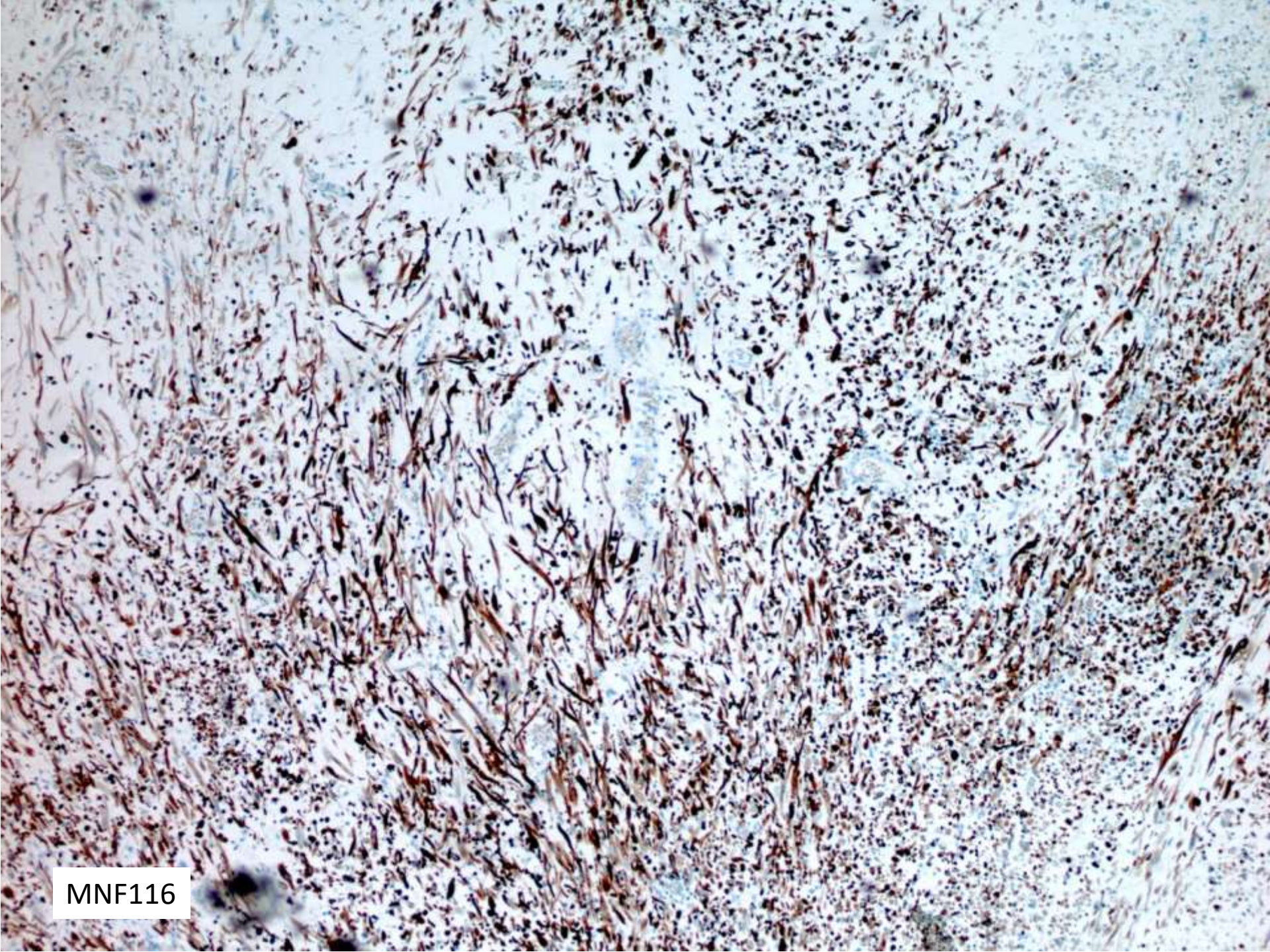




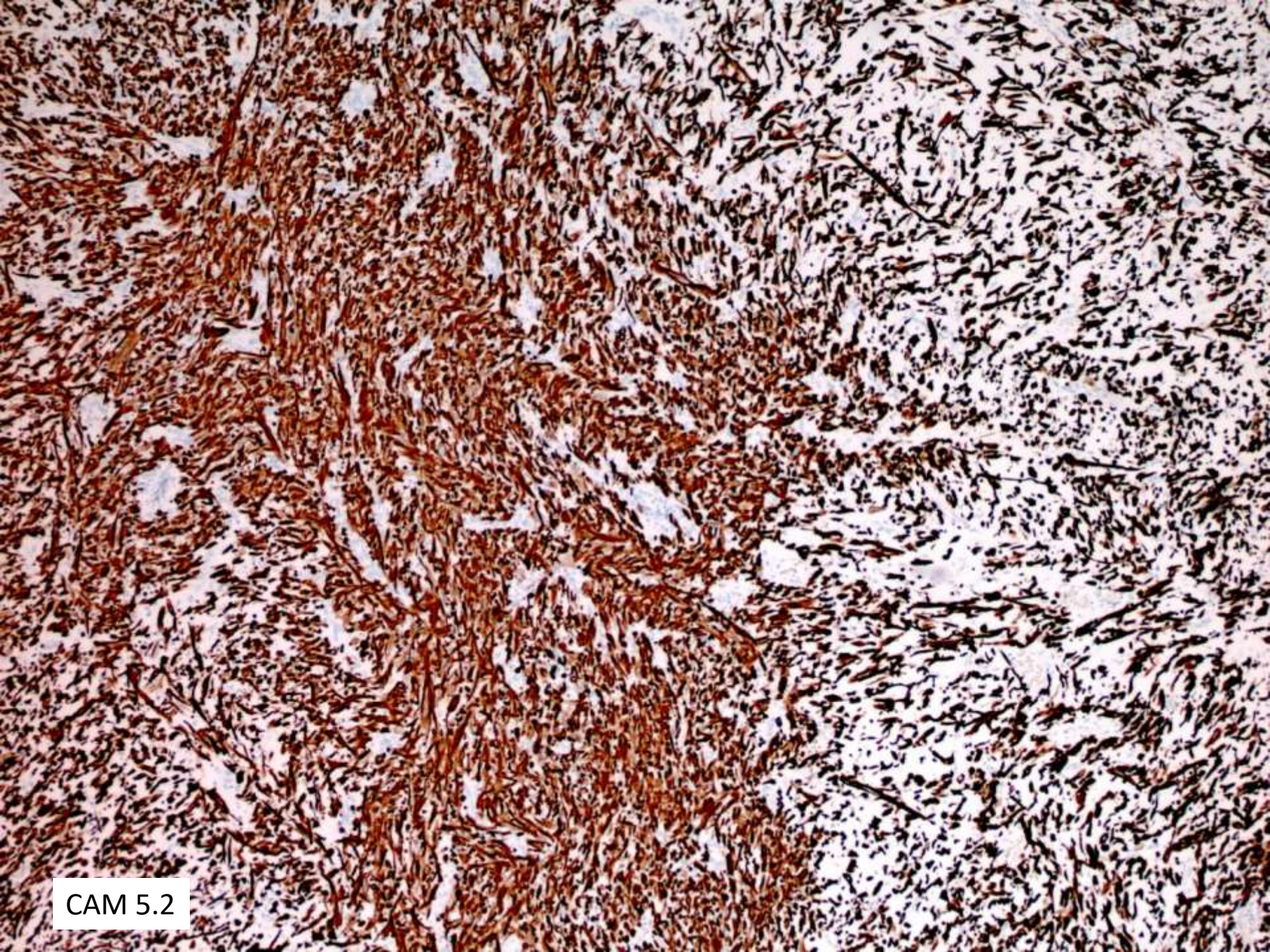
Alpha SMA



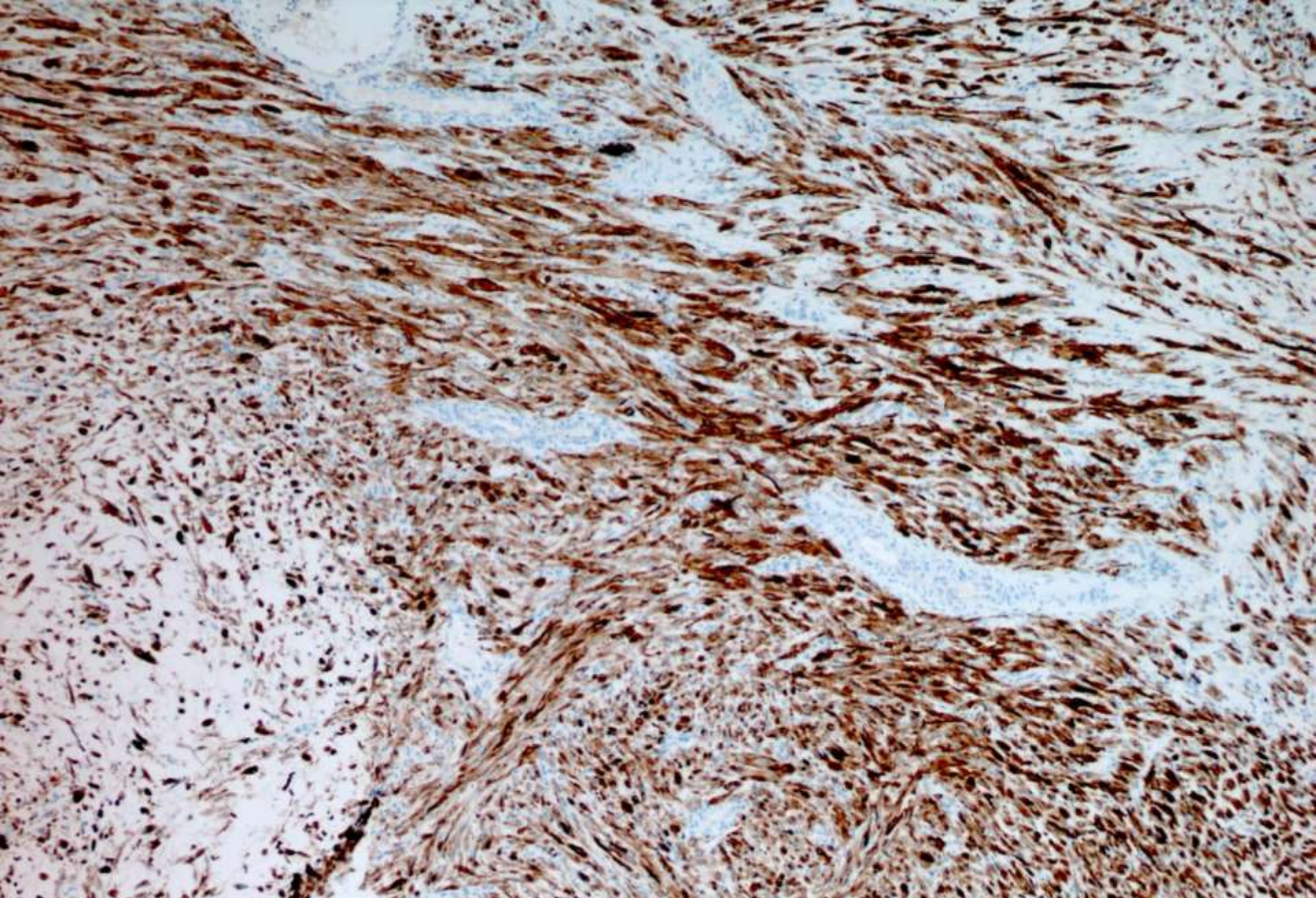
CK7



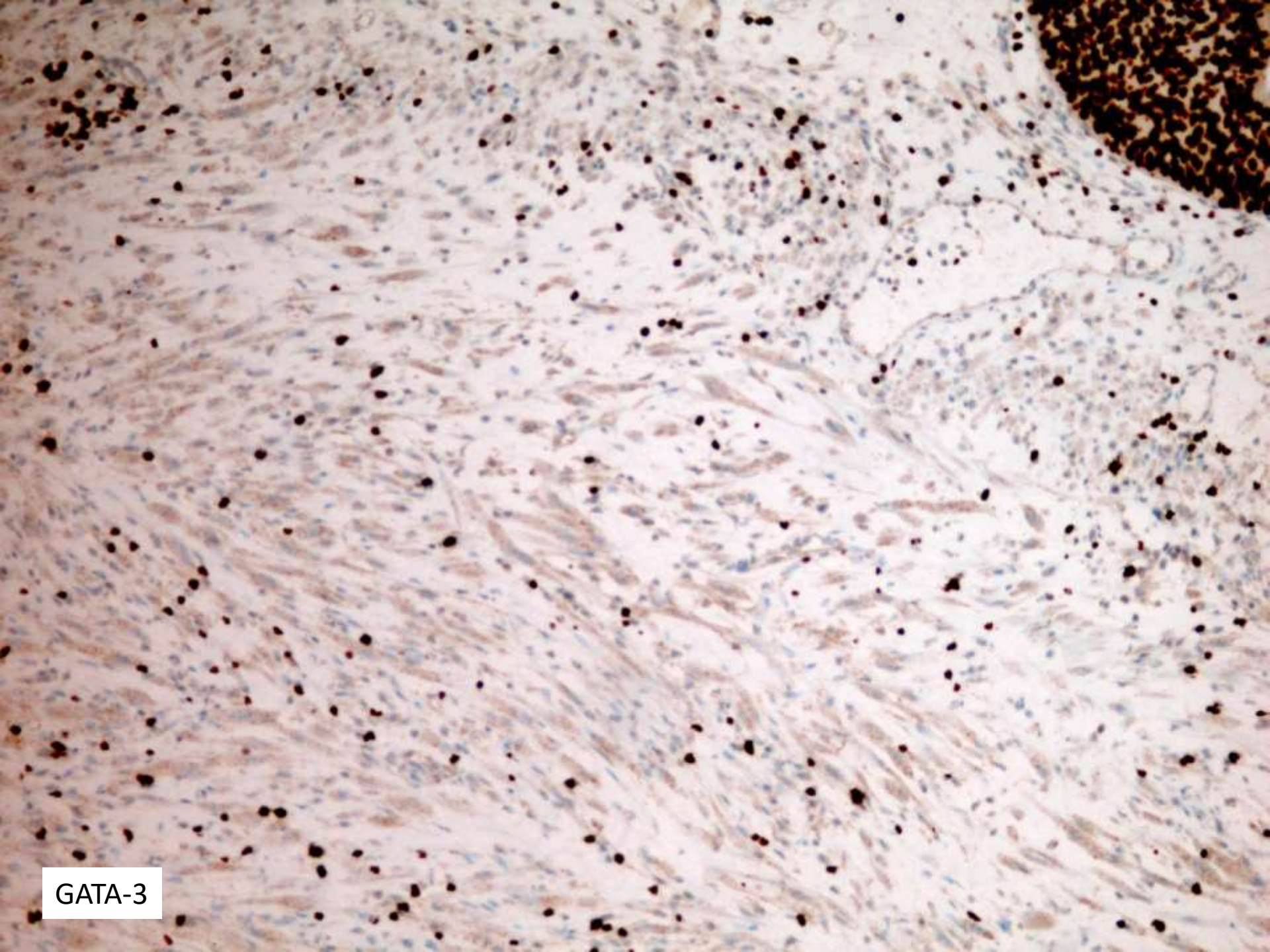MNF116



CAM 5.2



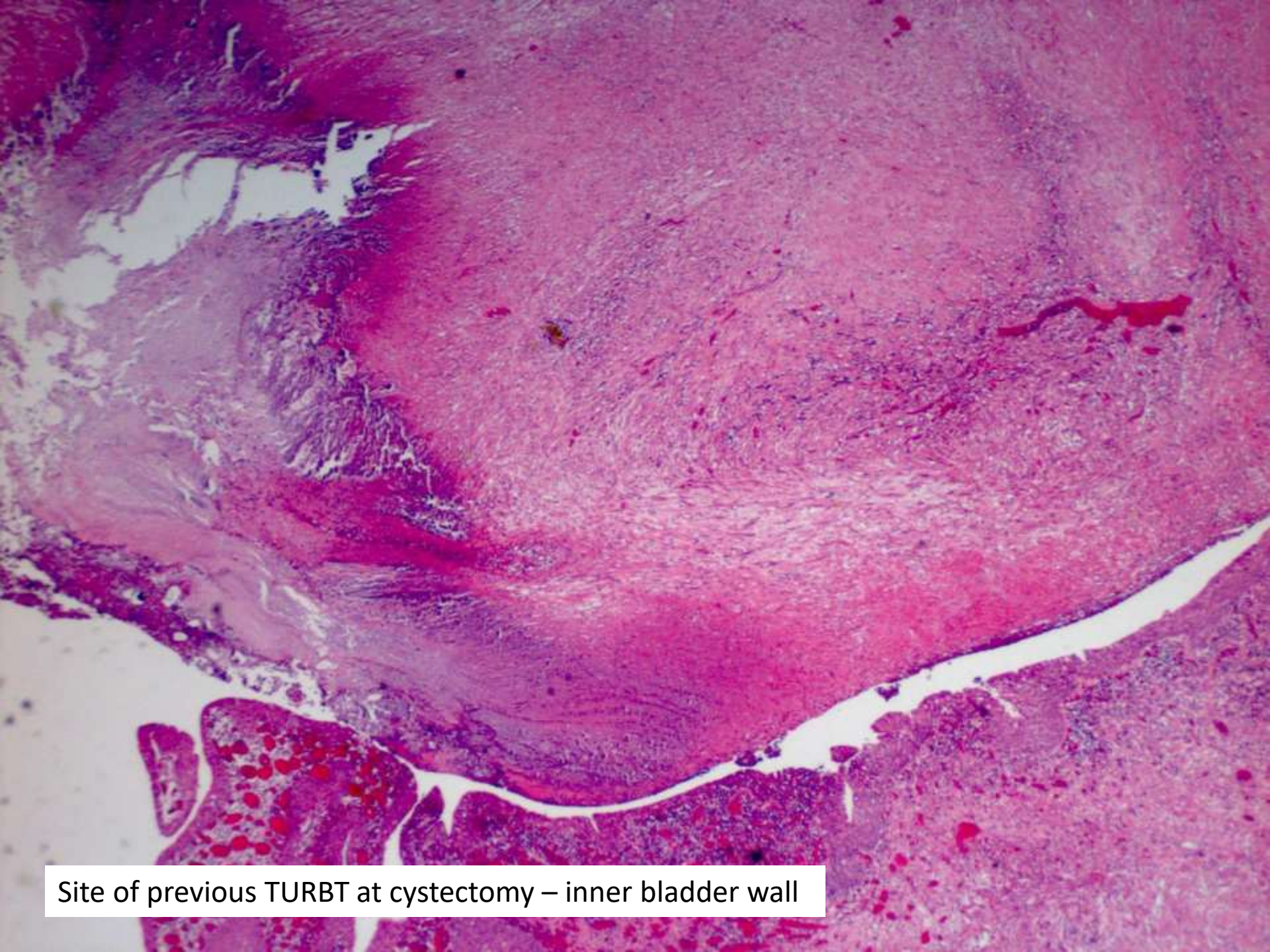ALK-1 [done retrospectively, after subsequent specimen]



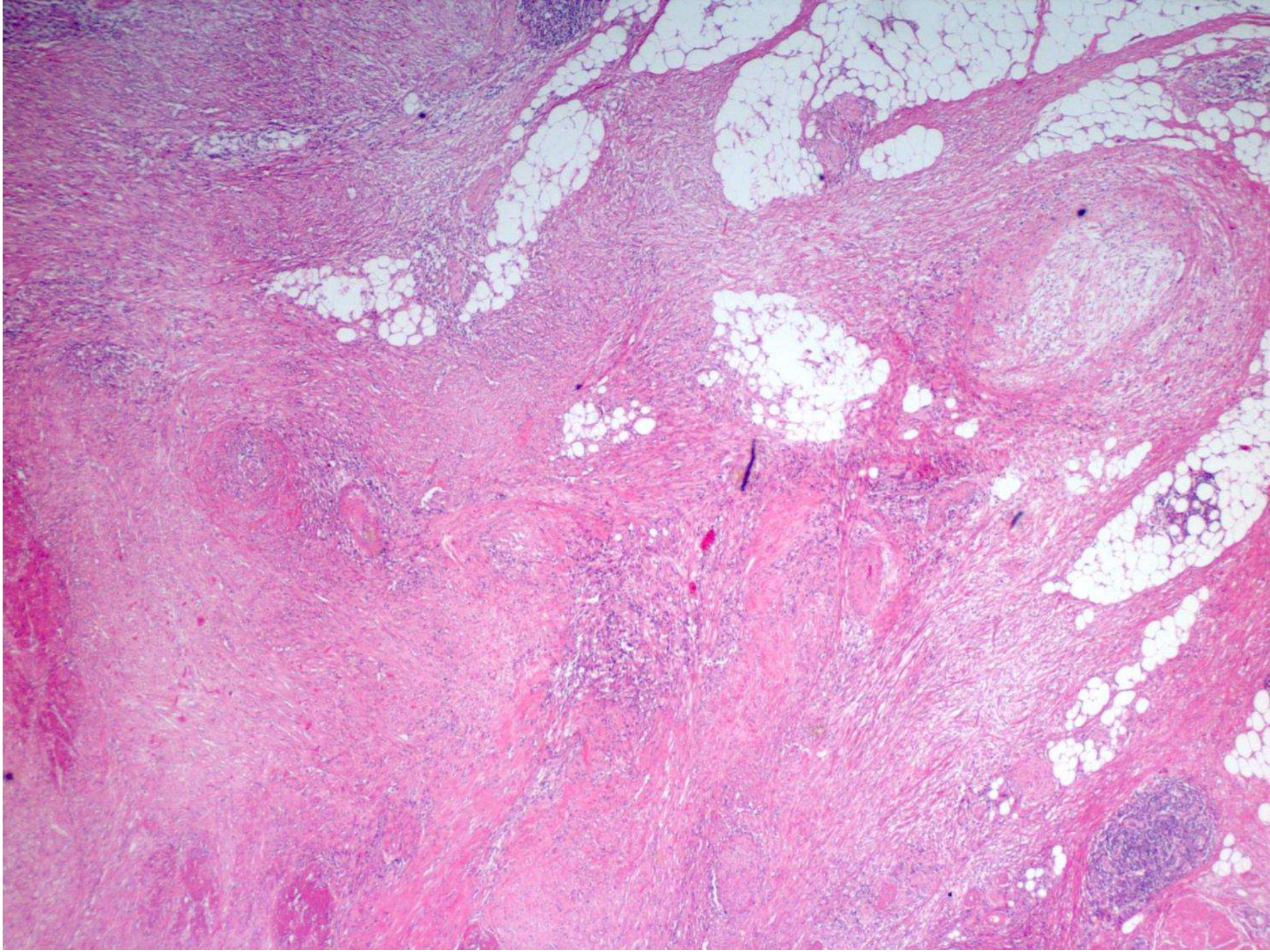
GATA-3

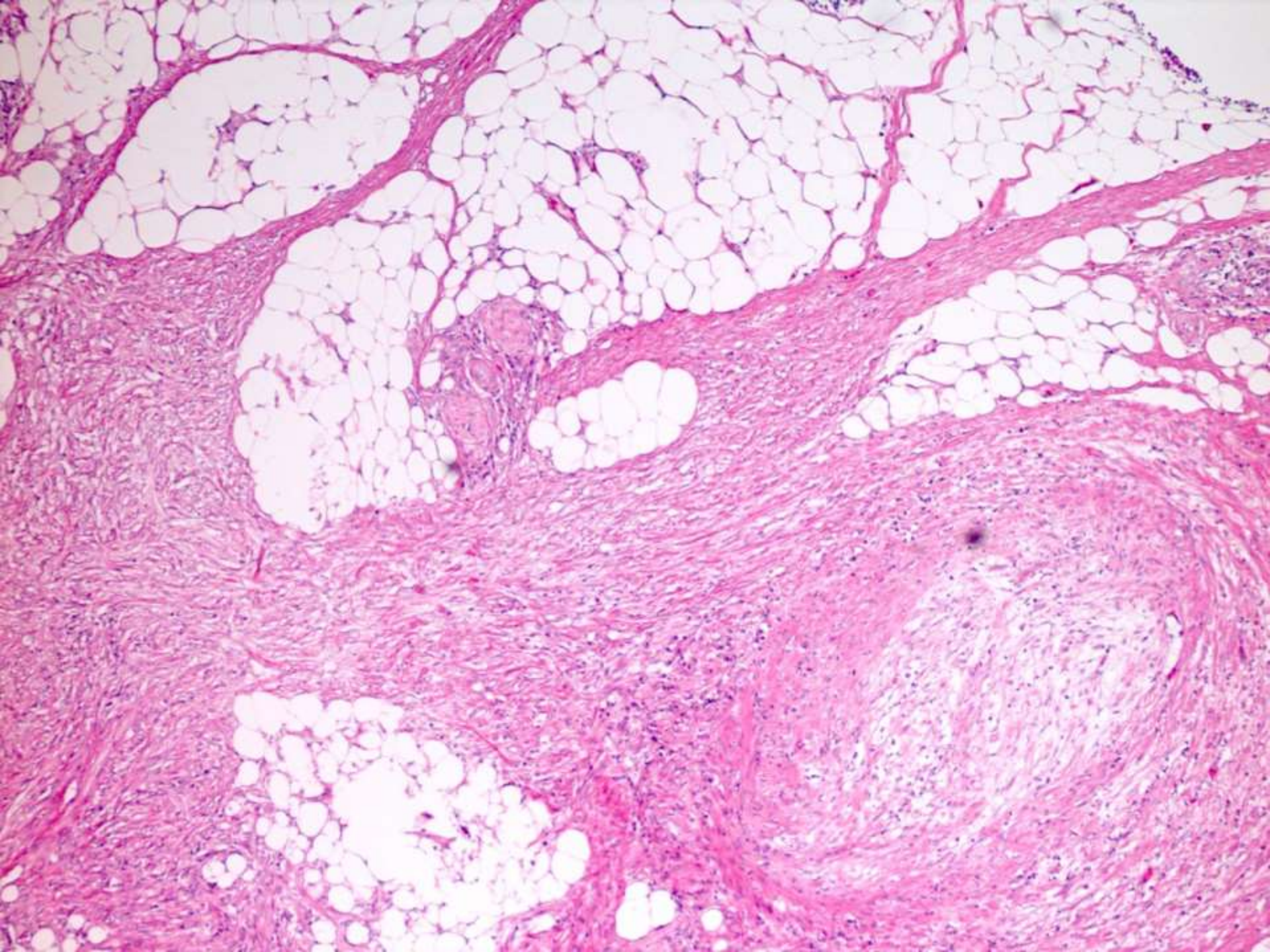
# Later

- Had radical cystectomy and hysterectomy with lymph node dissections
- In the wall of the bladder in one area was a 15 mm area of residual lesion (measured macroscopically, extending to perivesical fat)
- Uterus, cervix and lymph nodes appeared normal

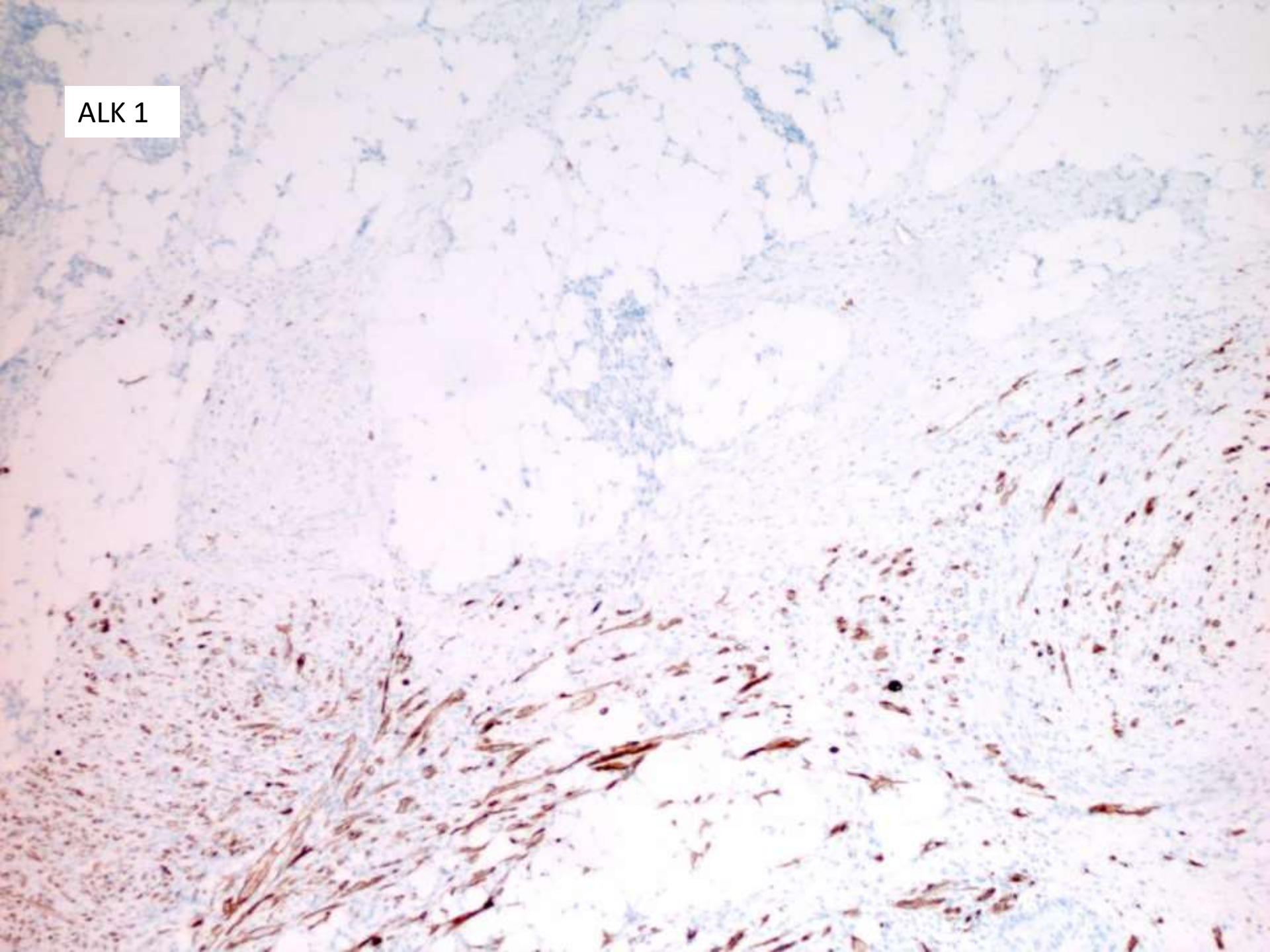


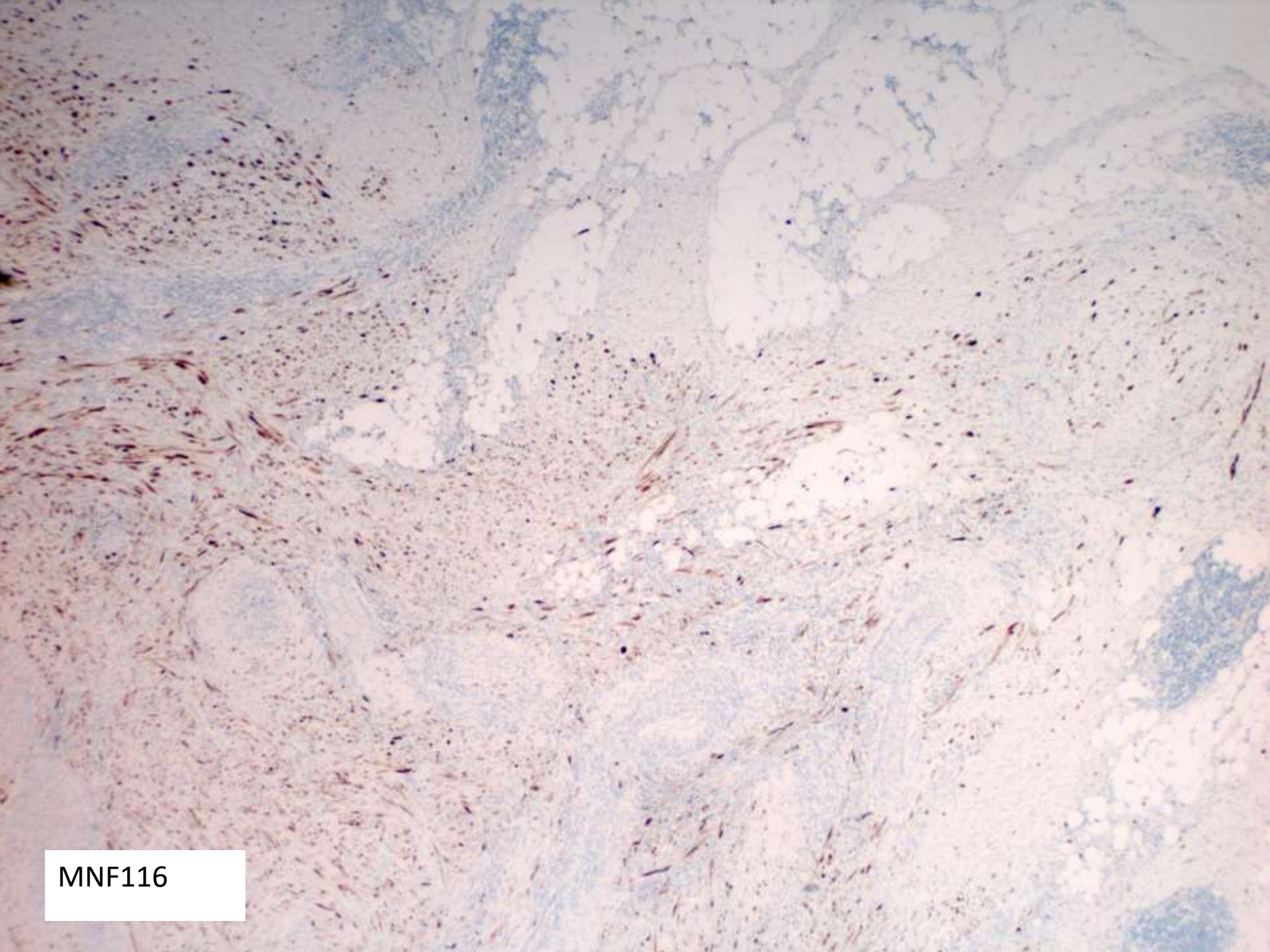
Site of previous TURBT at cystectomy – inner bladder wall





ALK 1





MNF116

# FISH analysis (performed on original TURBT)

- Fluorescence in situ hybridization (FISH) was performed with the ALK gene probe (Cytocell ALK Dual Colour, Break Apart) to detect rearrangements of 2p23
- A signal pattern consistent with ALK gene rearrangement was seen in multiple tissue areas examined.

# Diagnosis

Inflammatory myofibroblastic  
tumour/pseudosarcomatous myofibroblastic  
proliferation

# Similarities: bladder spindle cell lesions

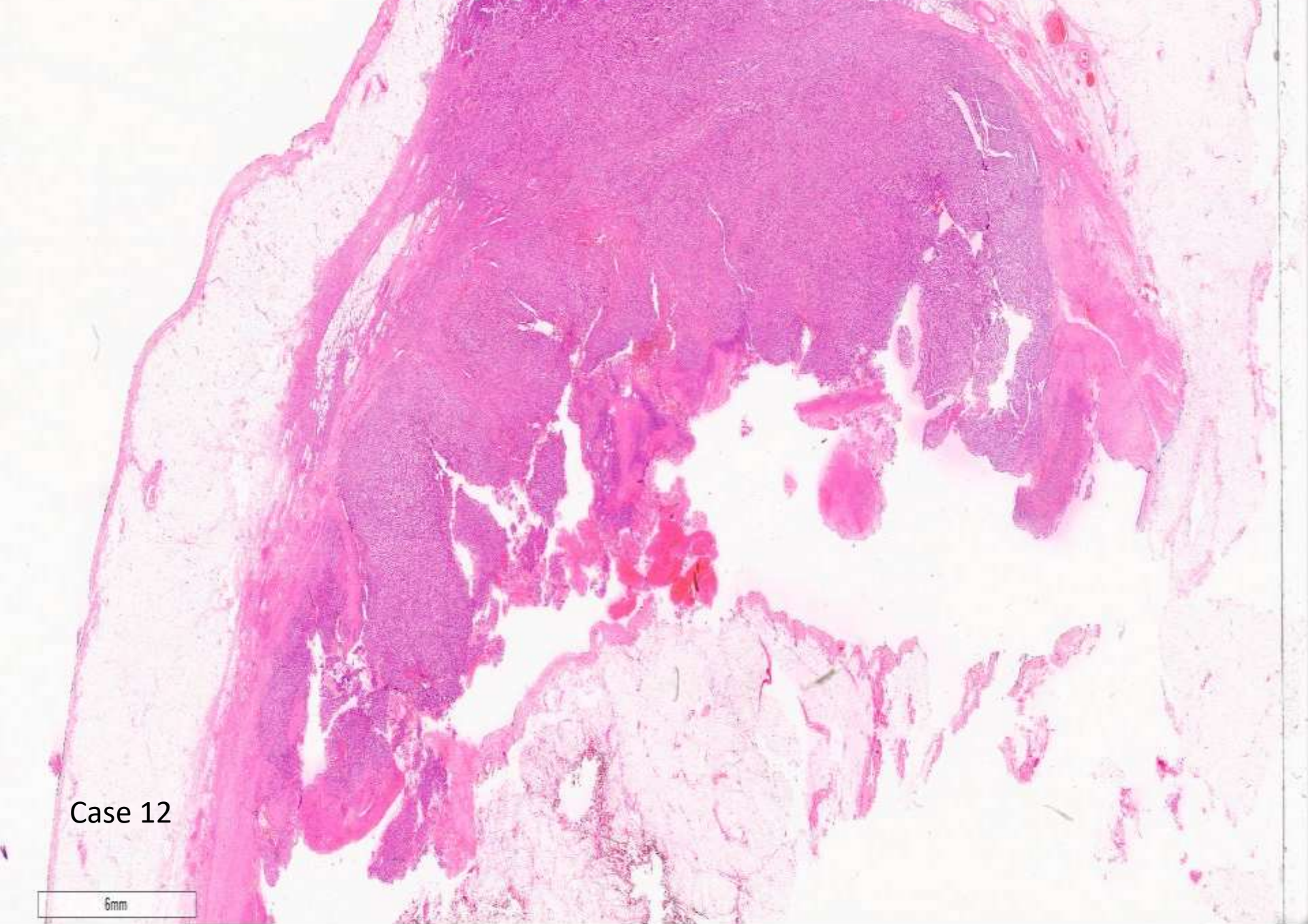
|                       | Spindle cells | Myxoid | Mitotic figures | Muscularis propria (detrusor) Involvement | alpha-SMA | Cytokeratins (broad spectrum e.g. MNF116 or AE1/3 or low molecular weight e.g. CAM 5.2) |
|-----------------------|---------------|--------|-----------------|---|-----------|---|
| IMT                   | +             | +/-    | +               | +/-                                       | +         | + [50% cases]/-   |
| Sarcoma               | +             | +/-    | +               | +/-                                       | +         | -/+   |
| Sarcomatoid carcinoma | +             | +/-    | +               | +/-                                       | -/+       | +/- [often focal]   |

# Differences: bladder spindle cell lesions

|                       | Nuclear pleomorphism with hyperchromasia | Abnorm mitotic figure(s) | Large/deep areas of necrosis | Prominent vascular background | In-situ carcinoma +/- obvious epithelial areas | ALK-1                                    | CK5/6            | 34BE12           | p63 [would also do p40] |
|-----------------------|--|--------------------------|------------------------------|-------------------------------|--|--|------------------|------------------|-------------------------|
| IMT                   | -  | -                        | -/[rare]                     | +                             | -  | +/-<br>[<50% cases +ve; some rhabdo +ve] | -                | -                | -                       |
| LMS                   | +  | +/-                      | +/-                          | -                             | -  | -  | -                | -                | -/+<br>[23% focal +ve]* |
| Sarcomatoid carcinoma | +  | +/-                      | +/-                          | -                             | +/-  | -  | -/+<br>[27% +ve] | -/+<br>[25% +ve] | +/-<br>[50% +ve]        |

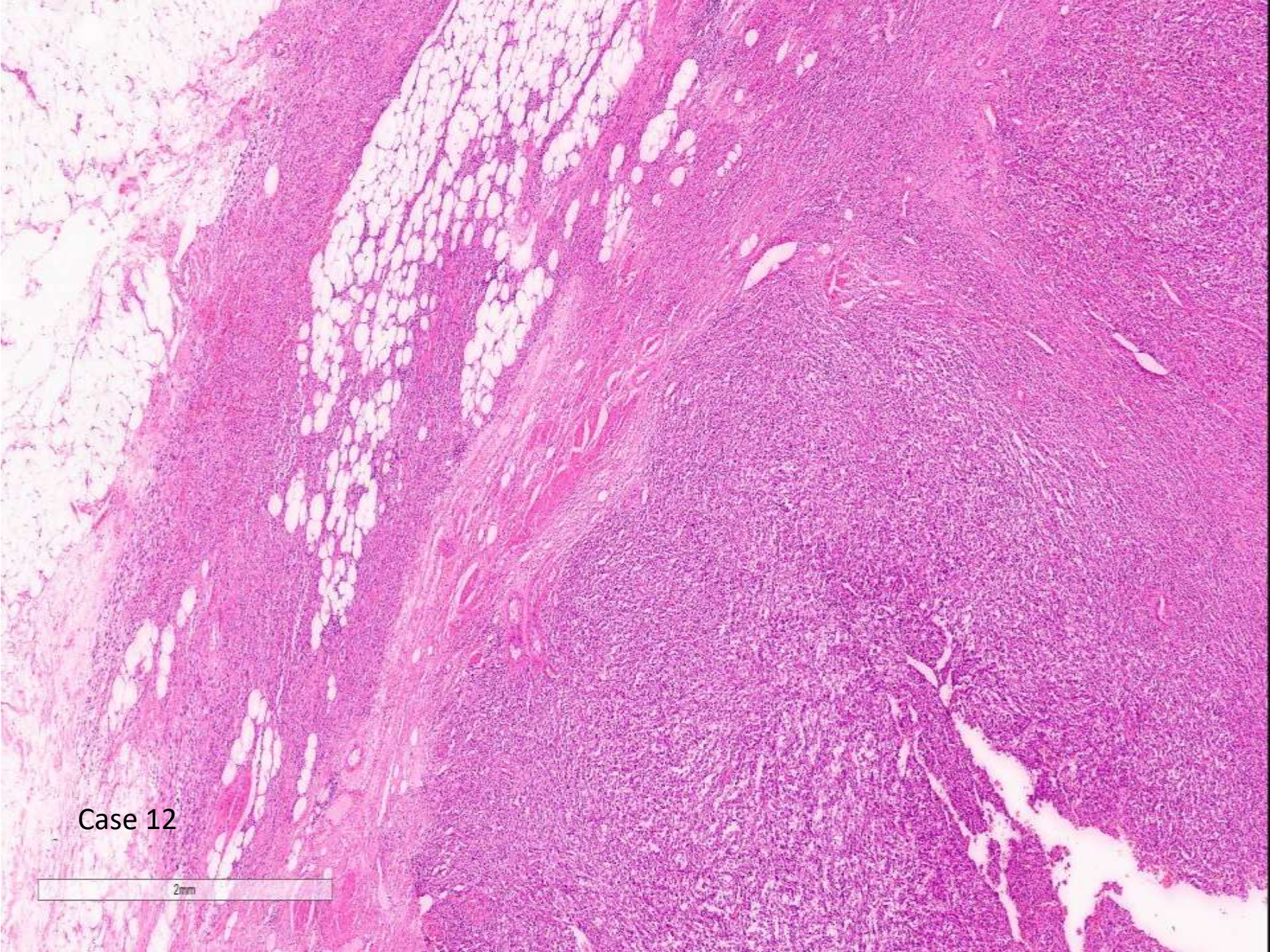
# History:

- Female 62 years old
- “MIBC – undifferentiated TCC with sarcomatoid features. Radiologically pT3b. Radical anterior pelvic clearance”
- Macroscopically the tumour was described as involving the bladder and forming a large exophytic necrotic mass measuring 60 mm in maximum dimension, invading through the muscle of the bladder to the perivesical tissue. The uterus, Fallopian tubes and ovaries were described as unremarkable macroscopically [and histologically].



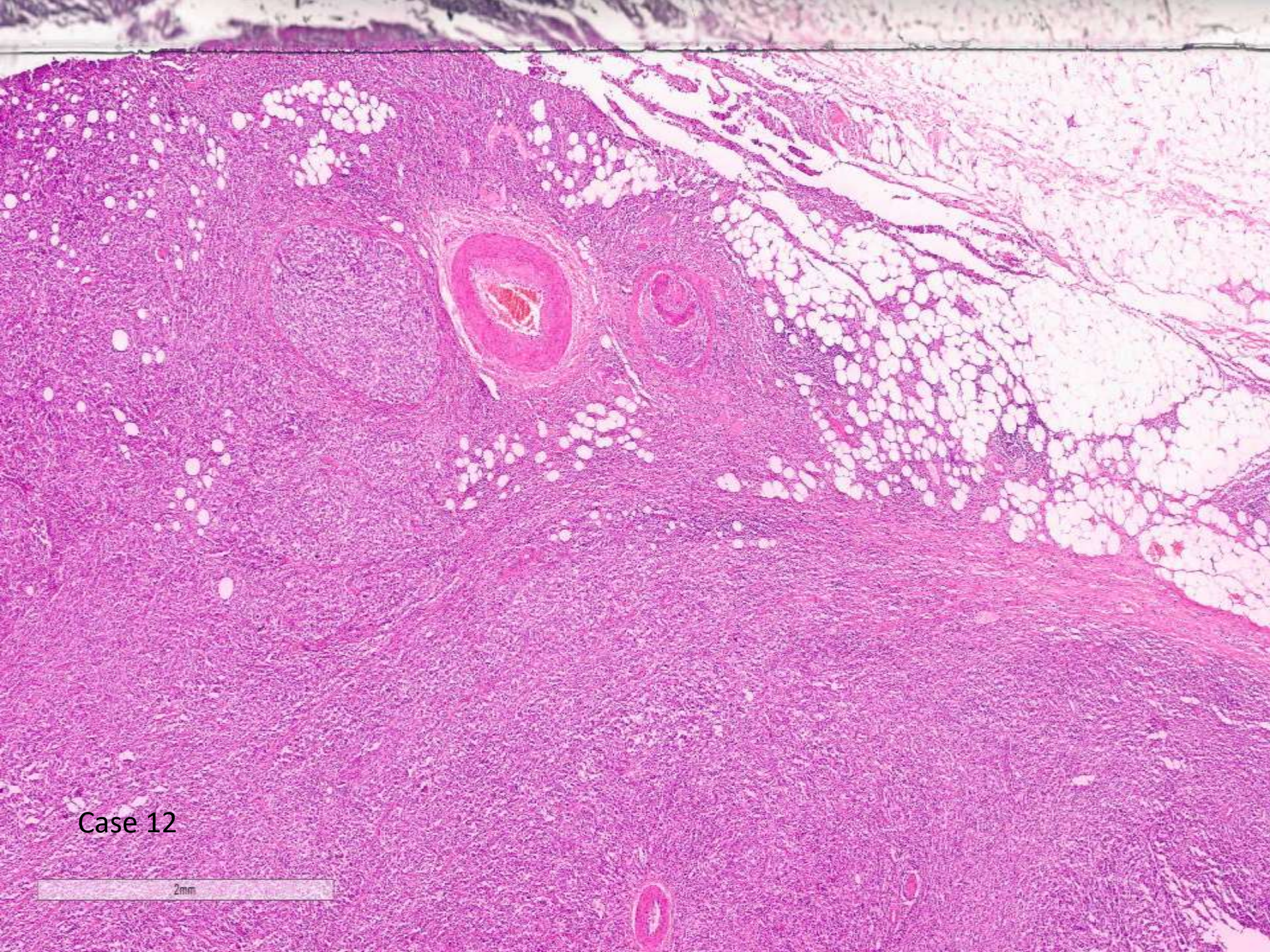
Case 12

6mm



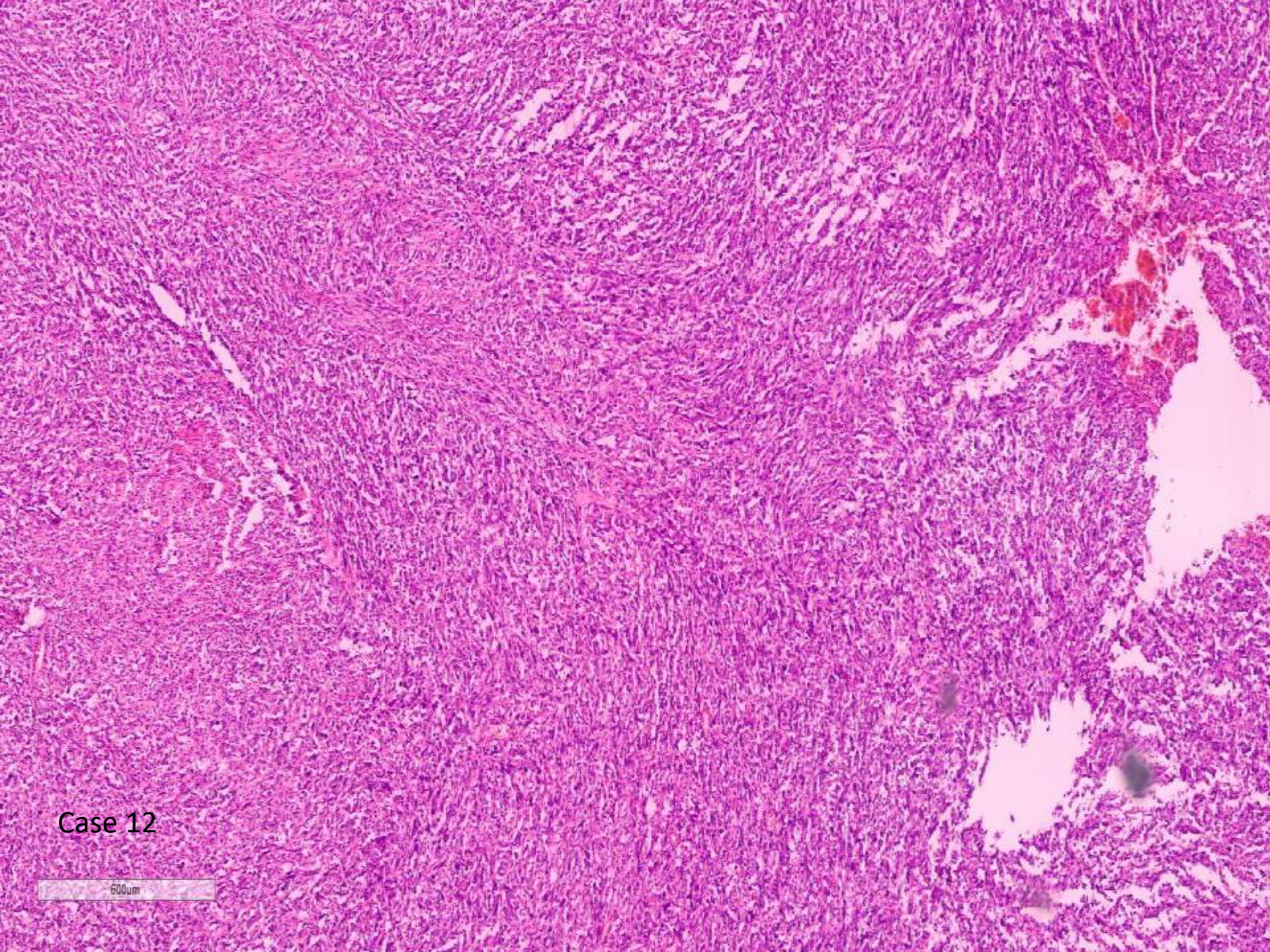
Case 12

2mm



Case 12

2mm



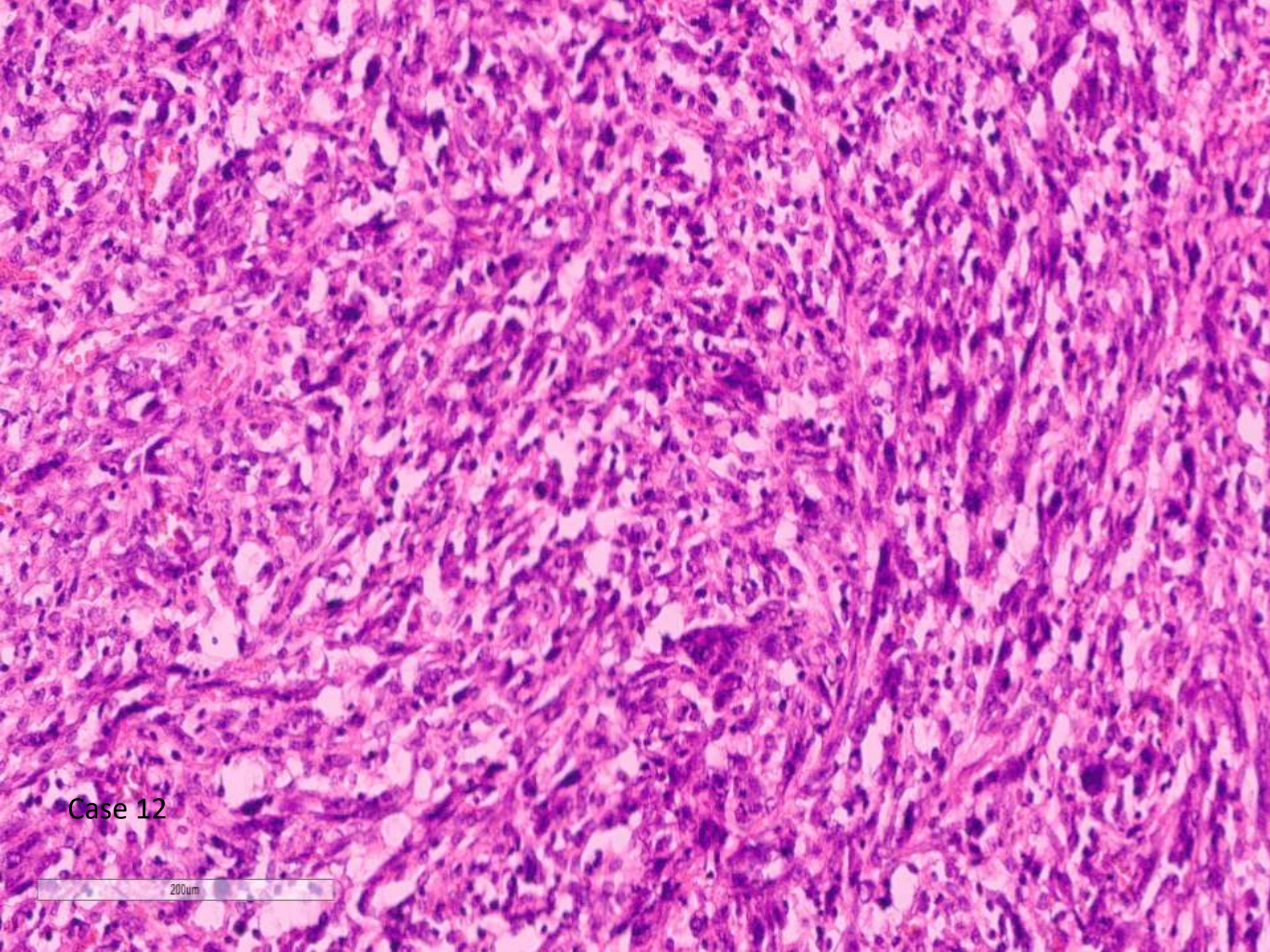
Case 12

600um

Case 12

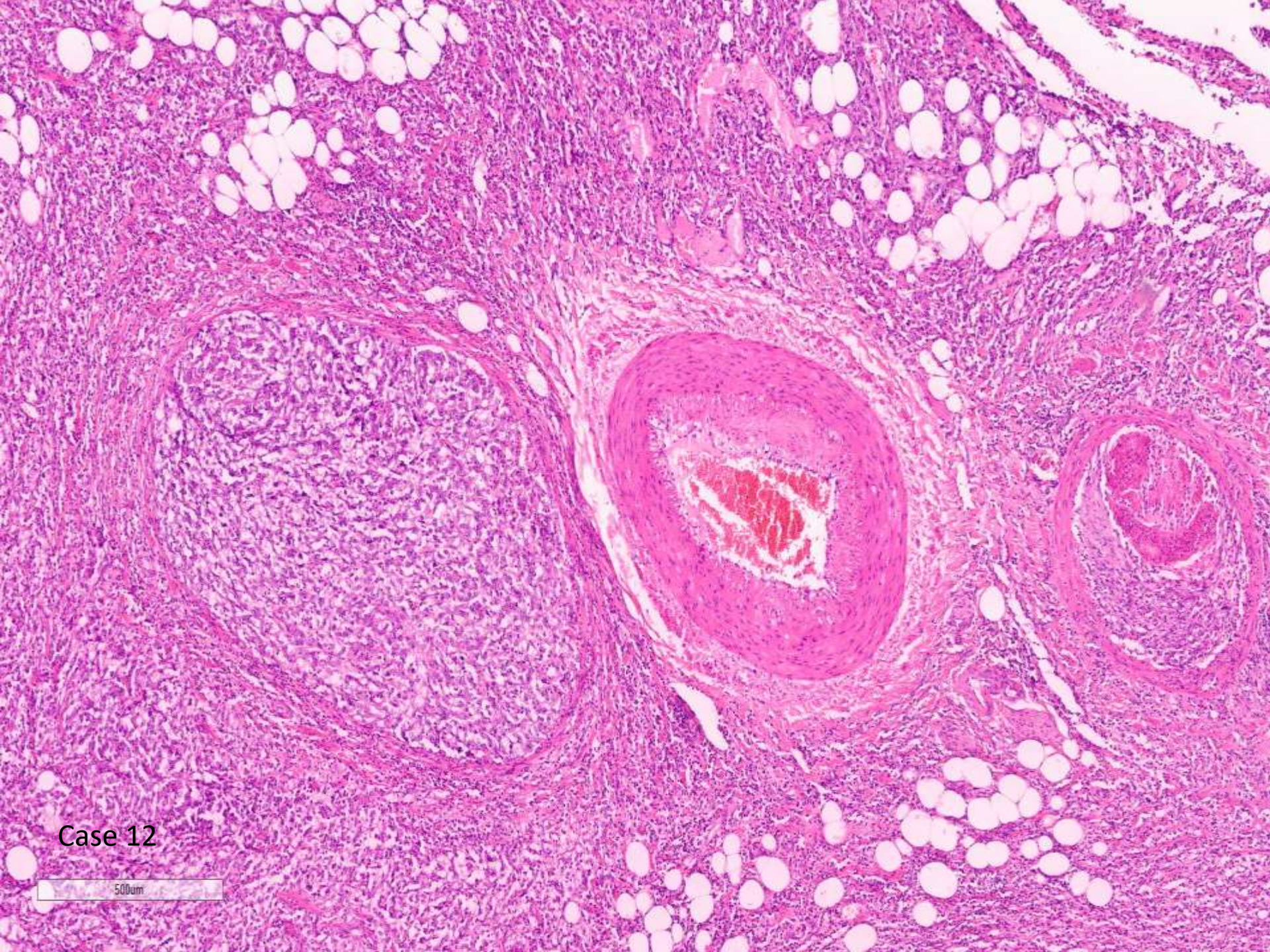
300um





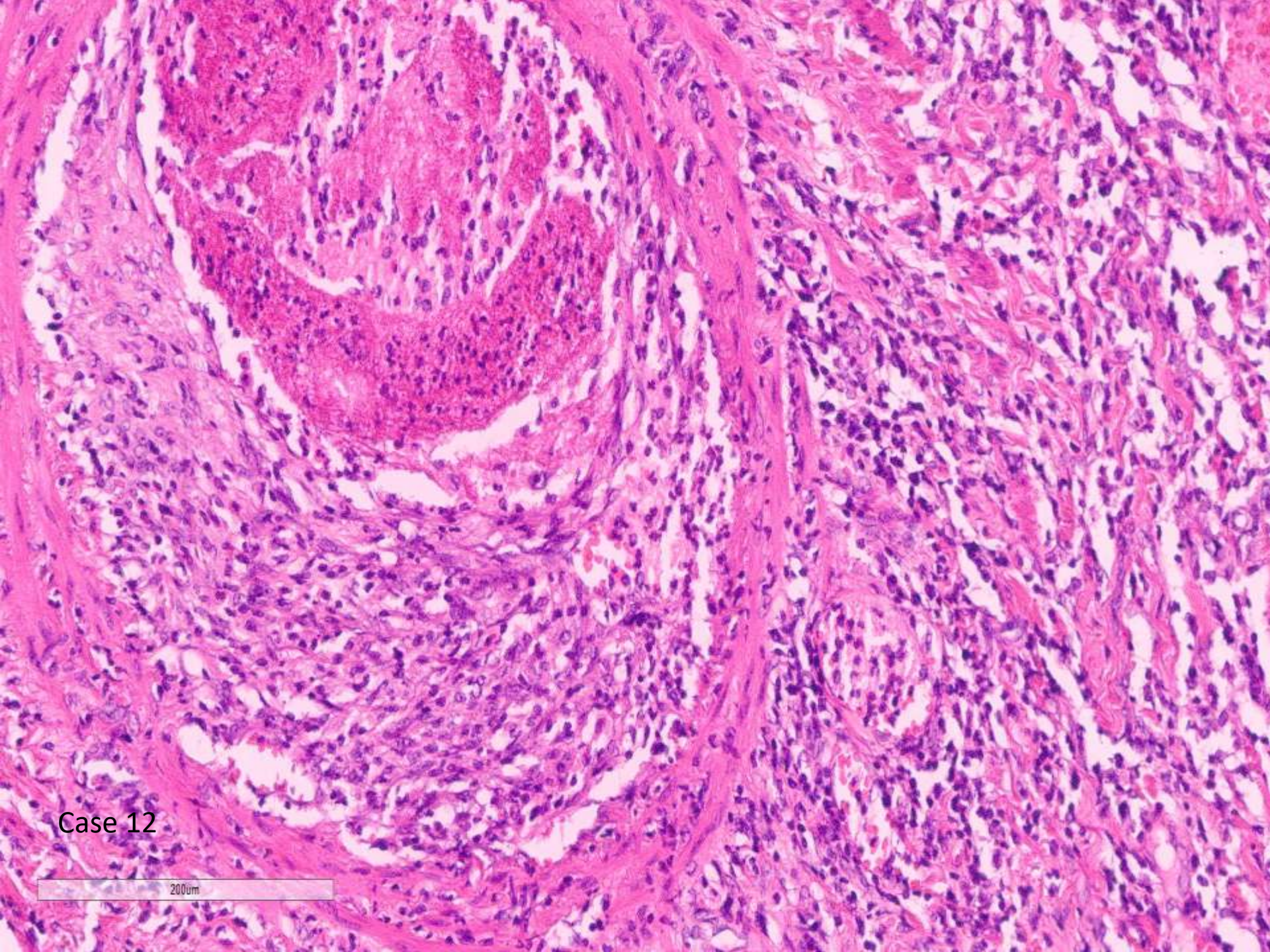
Case 12

200um



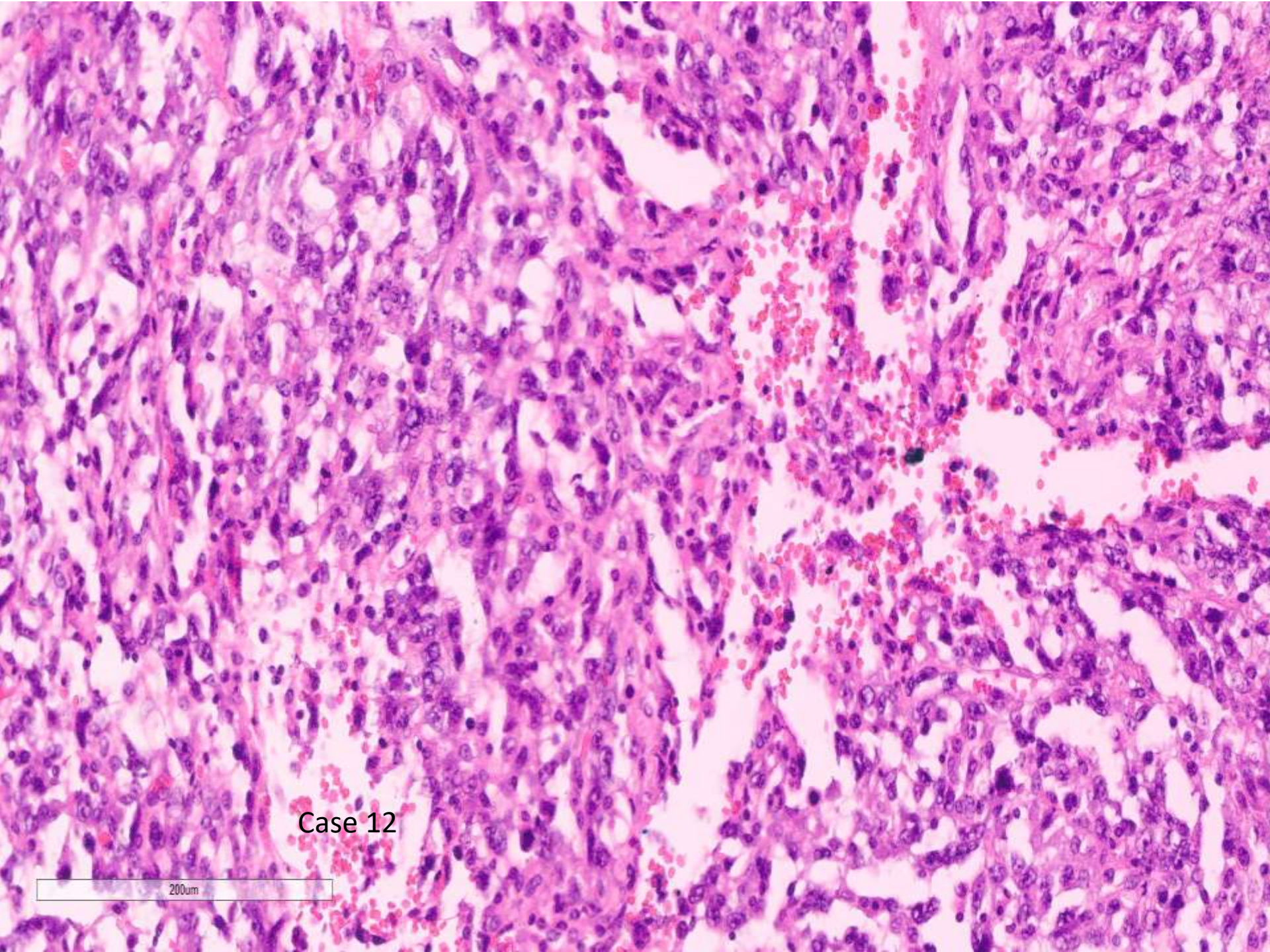
Case 12

500um



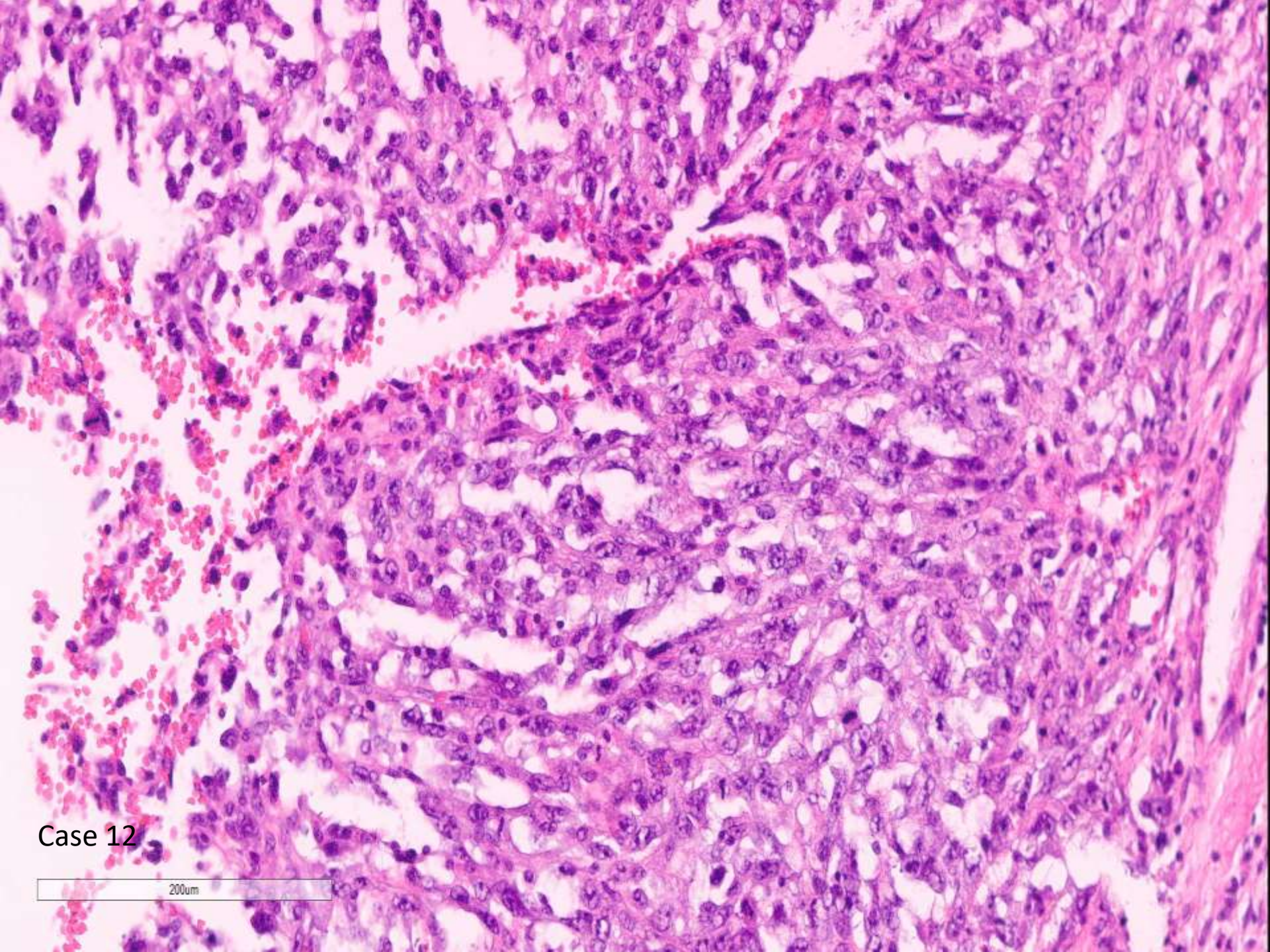
Case 12

200um



Case 12

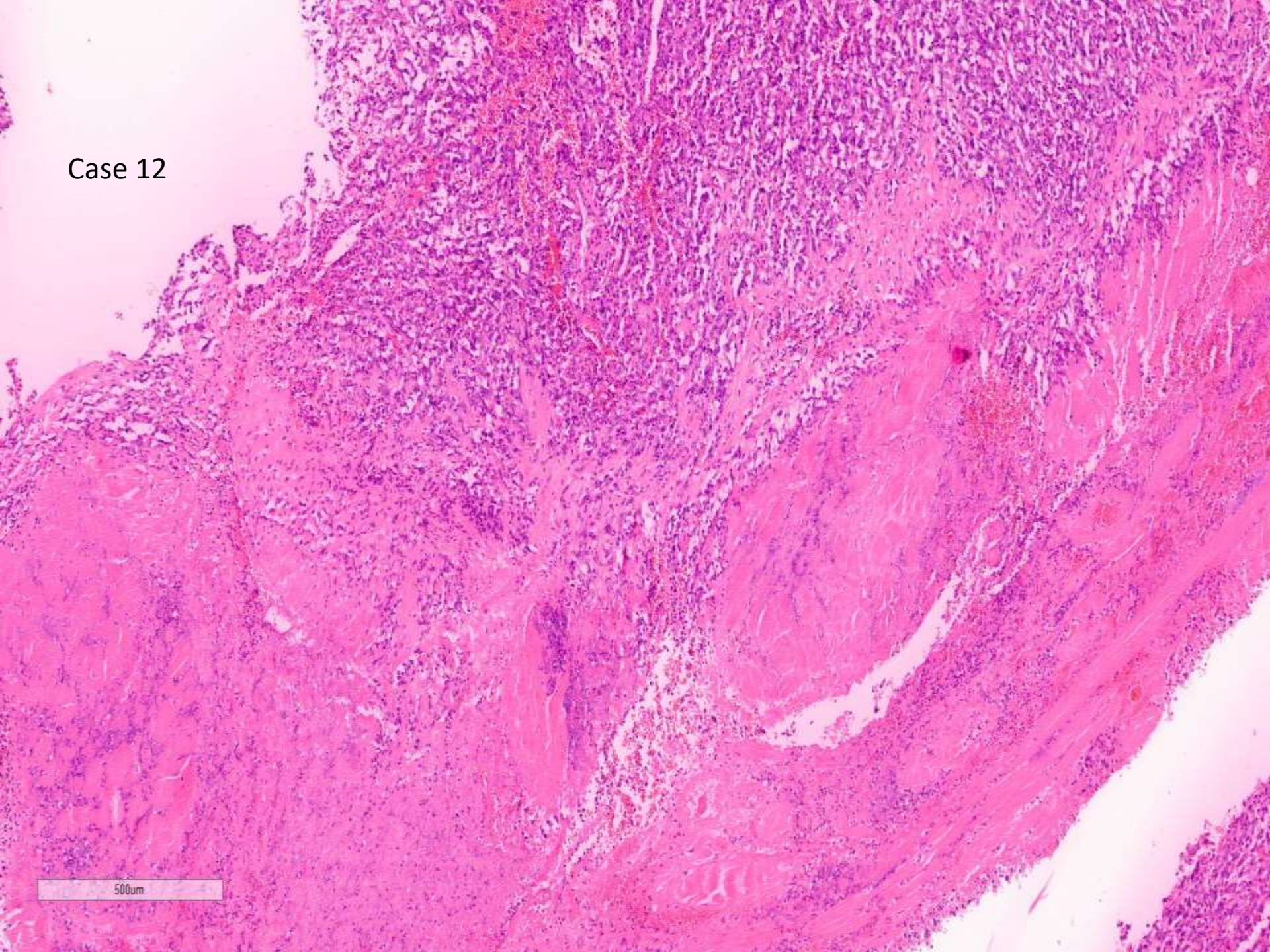
200um



Case 12

200um

Case 12



500um

# Immunohistochemistry

## Positive

- AE1/3, CK7 (focal scanty staining of scattered lesional cells near the surface; -ve in deeper spindle cell areas)
- CAM5.2 (very focal/very minimal; -ve in deeper spindle cell areas)
- SMA (patchy/weak)
- Vimentin (strong/diffuse)

## Negative

- 34betaE12 (surface ep only)
- CK5/6 (ditto)
- p40 (ditto)
- CK20 (umbrella cells on surface only)
- GATA3
- Uroplakin 2
- MNF116
- P63
- STAT-6
- CD34
- SOX10
- Melan A, HMB45, S100
- EMA
- CD21
- Desmin, myo D1, myogenon, caldesmon, calponin
- ALK-1
- CD45
- CD31, ERG
- CD68, CD163 (stain frequent histiocytes between tumour cells)

# Diagnosis

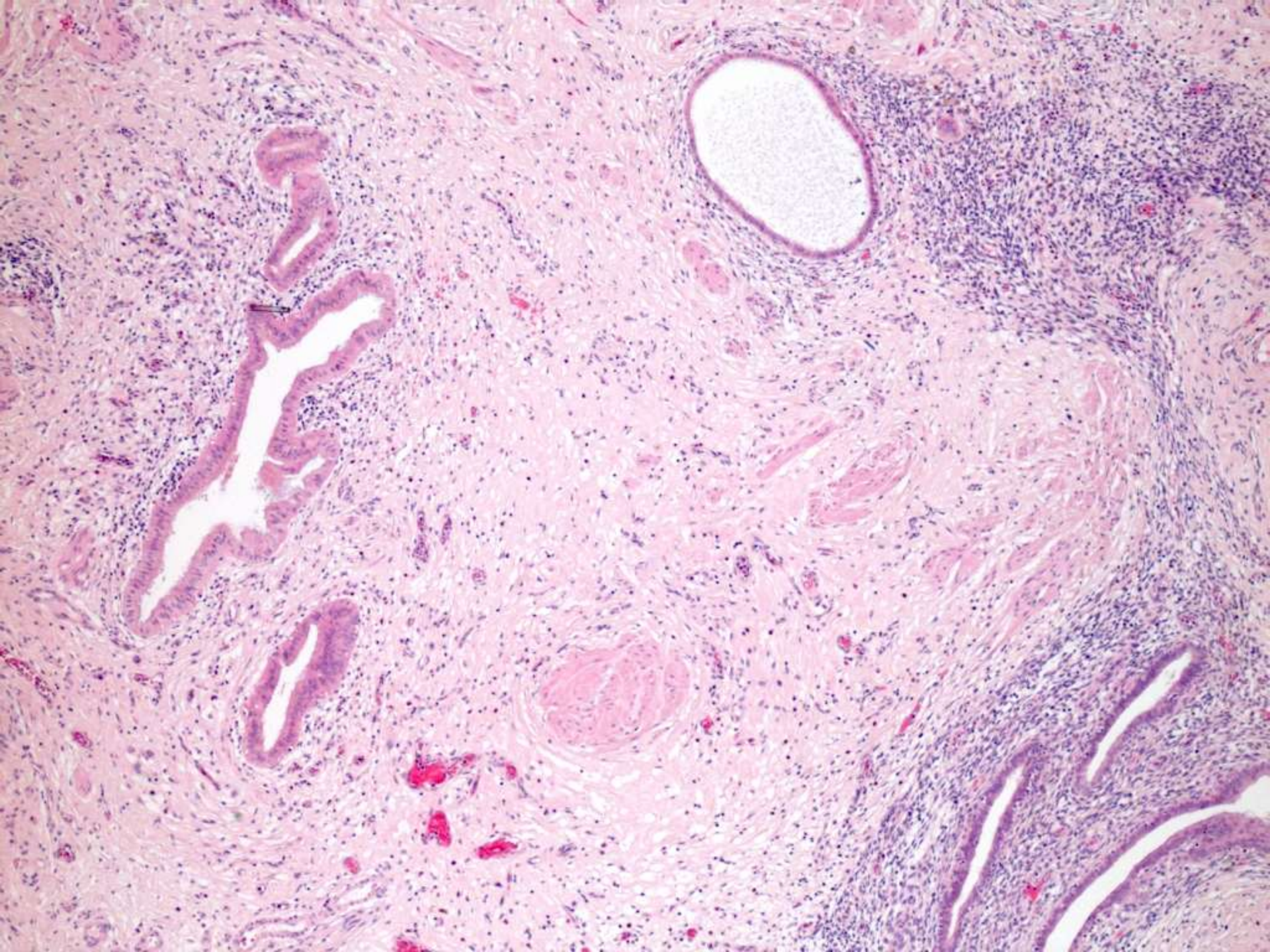
Malignant tumour with spindle cell morphology, difficult to prove but favouring sarcomatoid carcinoma (differential is high grade sarcoma)

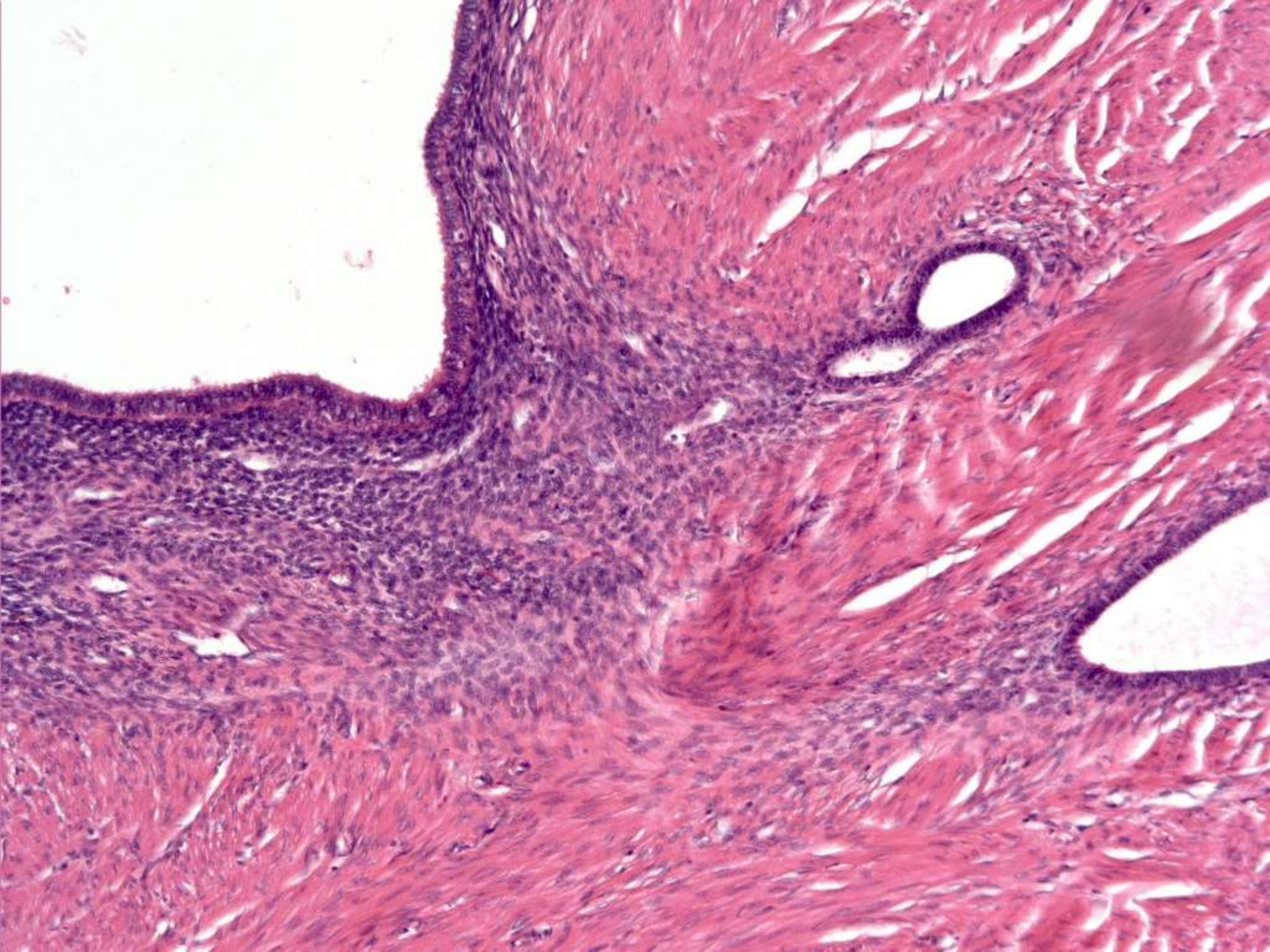
# Mullerianosis

Order of frequency: endometriosis > endocervicosis > endosalpingiosis

Endometriosis: lamina propria +/- muscularis propria. Glands, stroma, haemosiderin

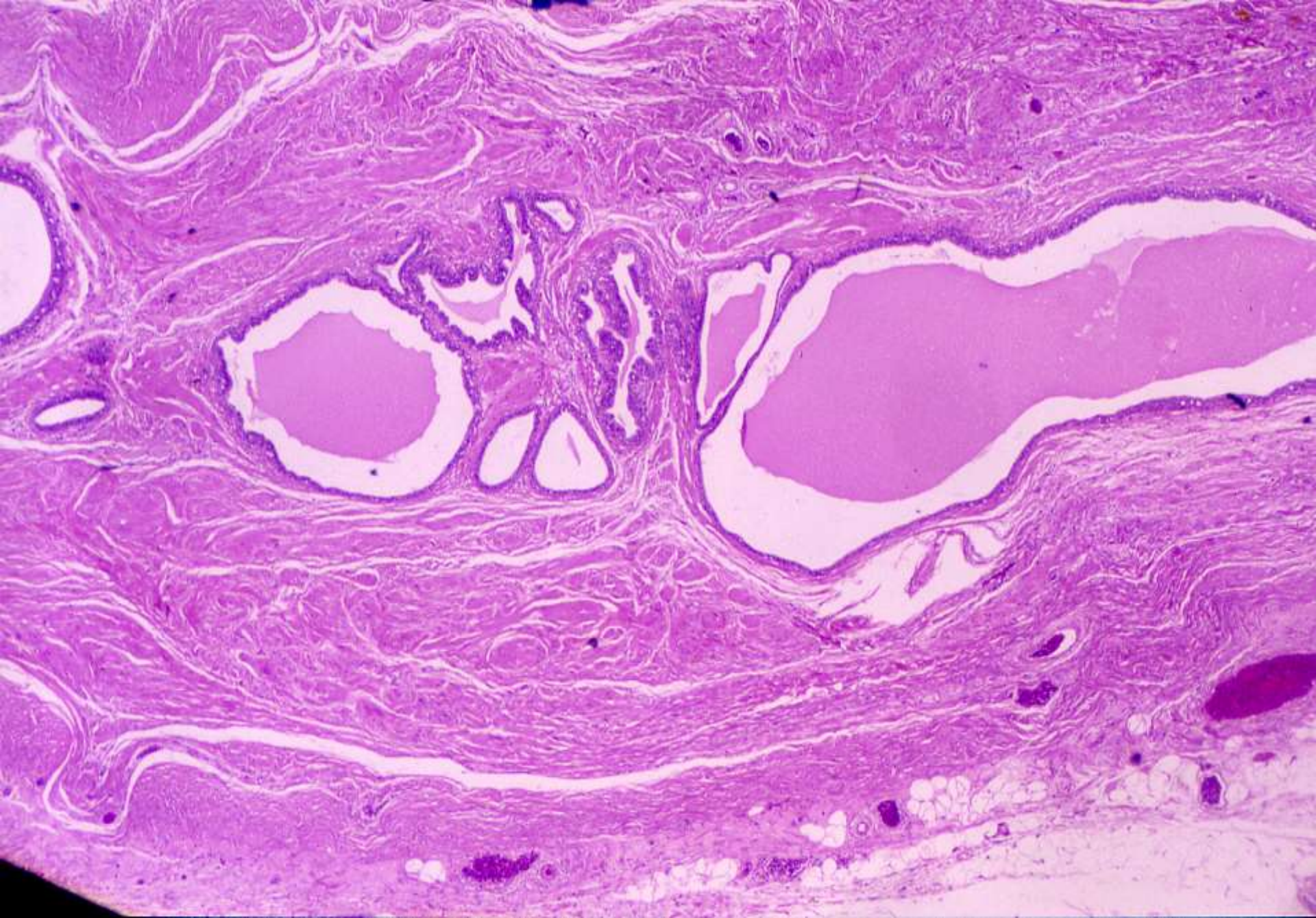
Endocervicosis: mass up to 5 cm.  
Endocervical type glands, haphazard distribution, including muscular propria

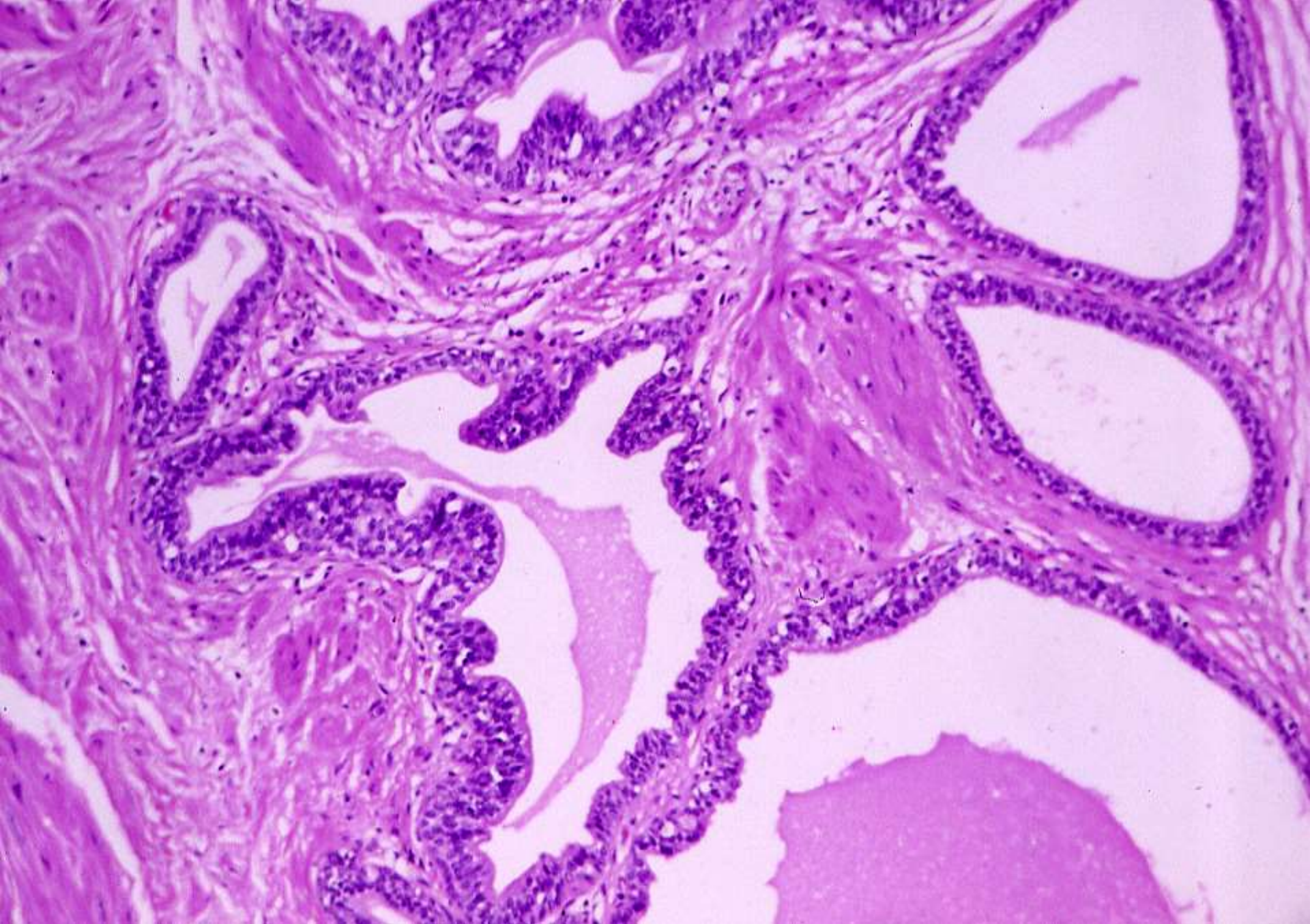


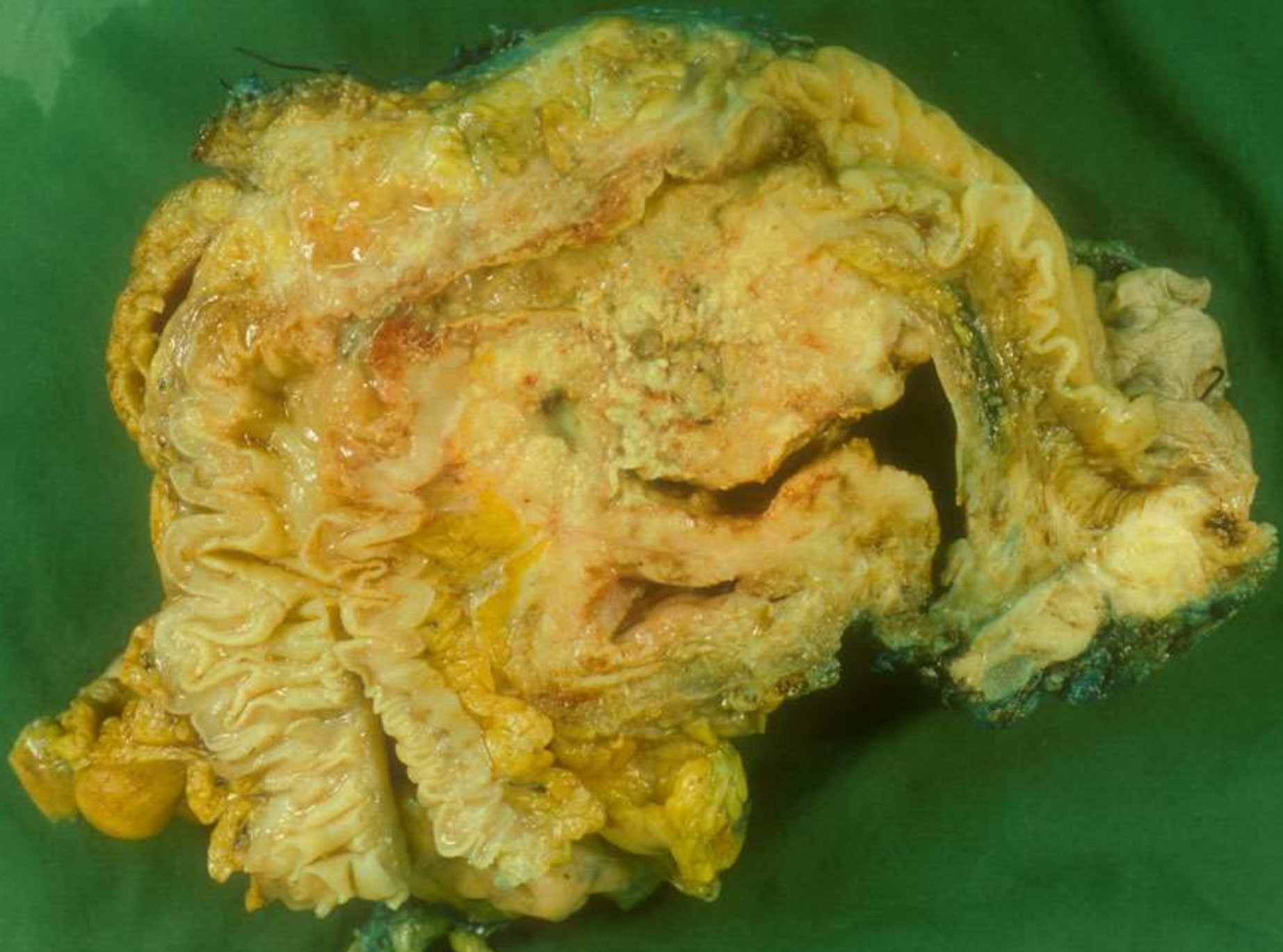


# Urachal remnants

- Cysts lined by urothelium, cuboidal or columnar epithelium or (in large cysts) flattened cells
- Extend into muscularis propria
- May harbour CIS and can mimic deep-seated bladder invasion





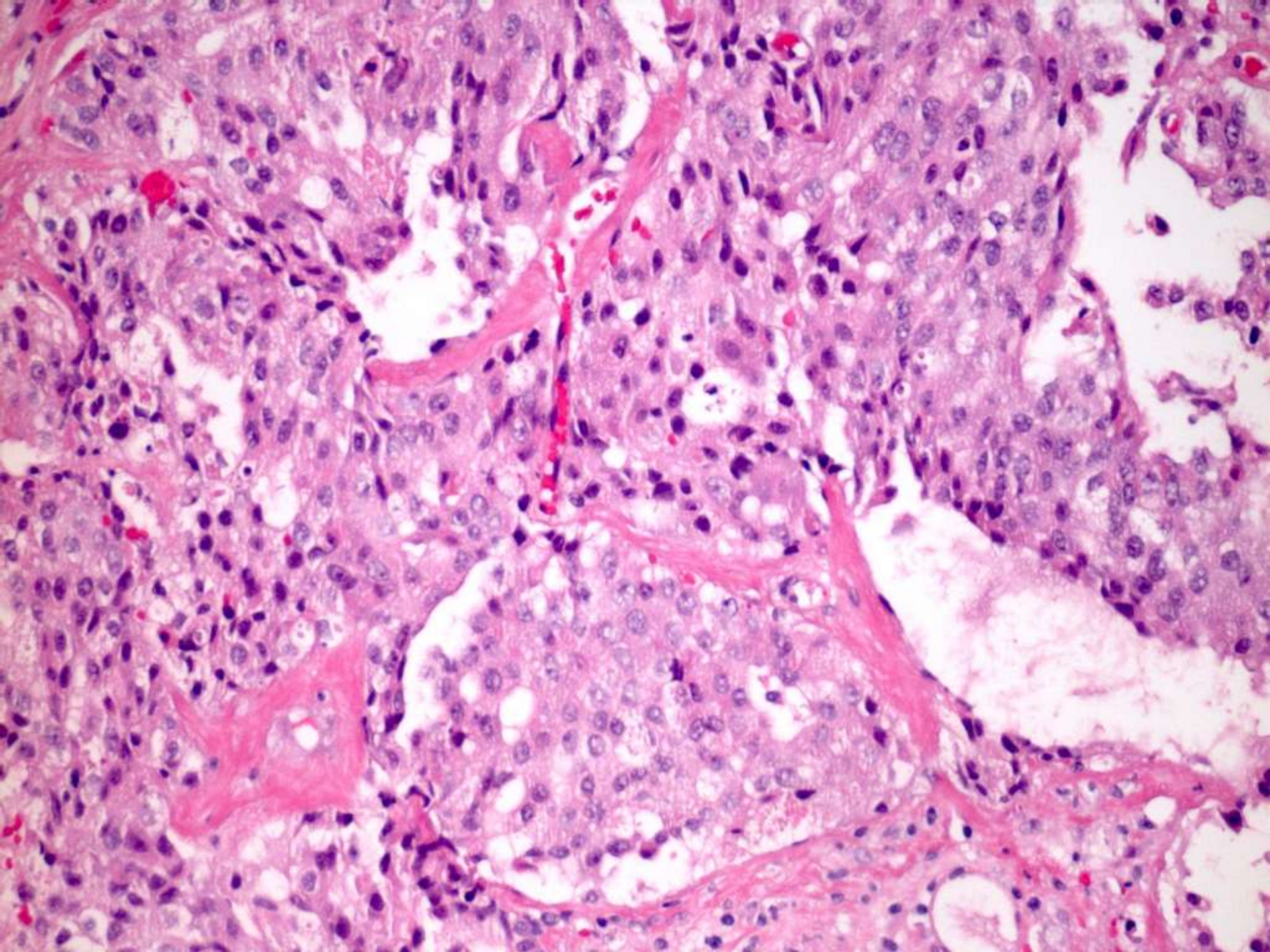


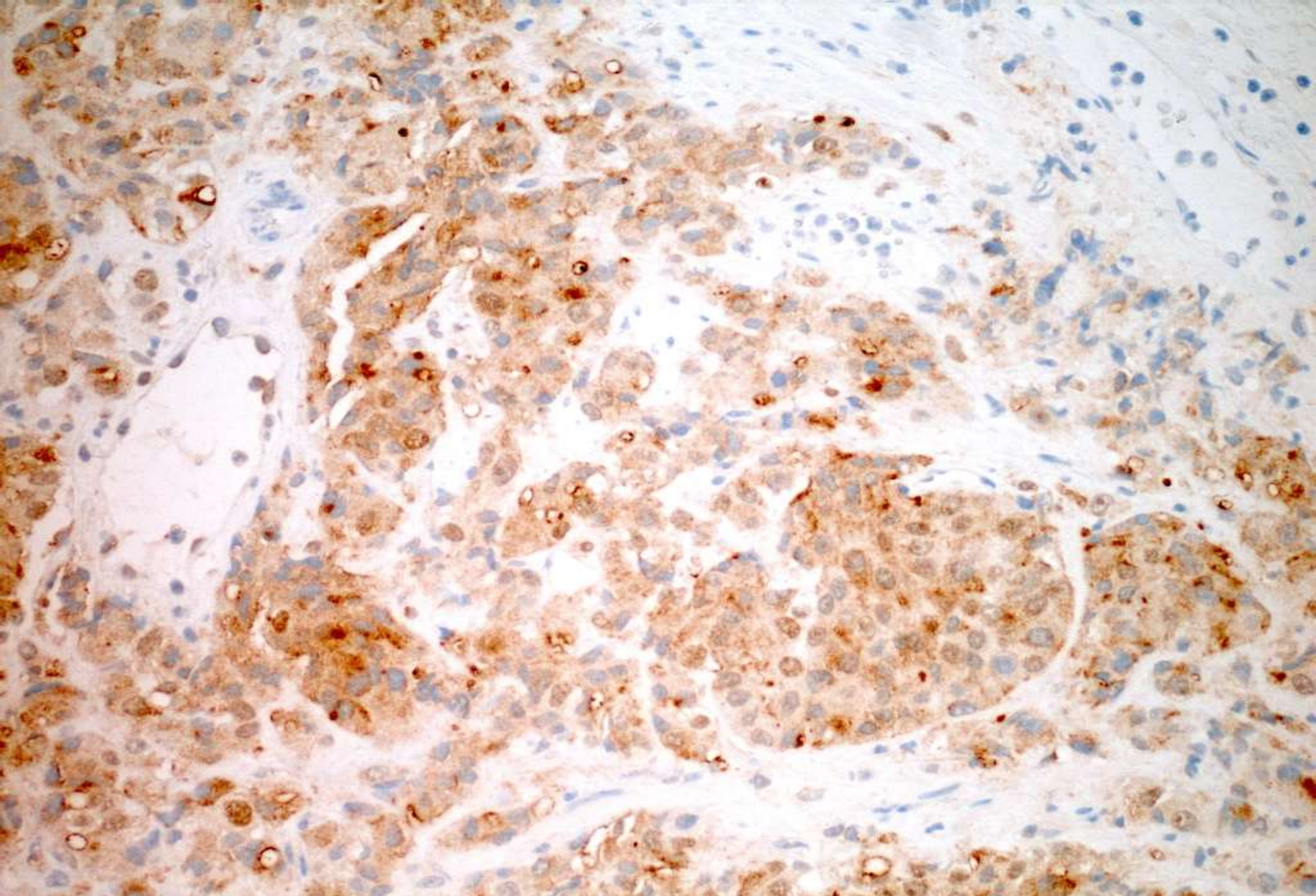
# Spread/metastasis of tumour from other organs

- Colon ( $\beta$ -catenin +/- [unreliable in my experience]): correlate with radiology/clinical. CDX2 only tells you enteric type; not site of origin!
- Prostate (NKX3.1 +ve [by far most sensitive prostate marker, much better than PSA!]; PSA +/-; prostate specific acid phosphatase +/-, AR +/-; CK7-/ +ve, CK20-/ +ve, 34 $\beta$ E12-ve, CK6/5-ve; GATA3 -ve; uroplakin 2 -ve).
- Cervix (squamous): correlate with radiol/clinical (p16 positivity won't help with differential diagnosis; HPV ish might well help)
- Others

# Remember

- For pure adenocarcinoma involving bladder, a primary elsewhere should be excluded clinically before accepting as a bladder primary, especially if there is no in-situ component
- Immunohistochemistry for some subtypes of adenocarcinoma (e.g. enteric) is differentiation-specific rather than primary site-specific
- For spread of squamous carcinoma from elsewhere versus urothelial carcinoma with squamous differentiation, p16 immunohistochemistry will not be helpful, but HPV ISH may be. Correlation with clinical/radiology essential!

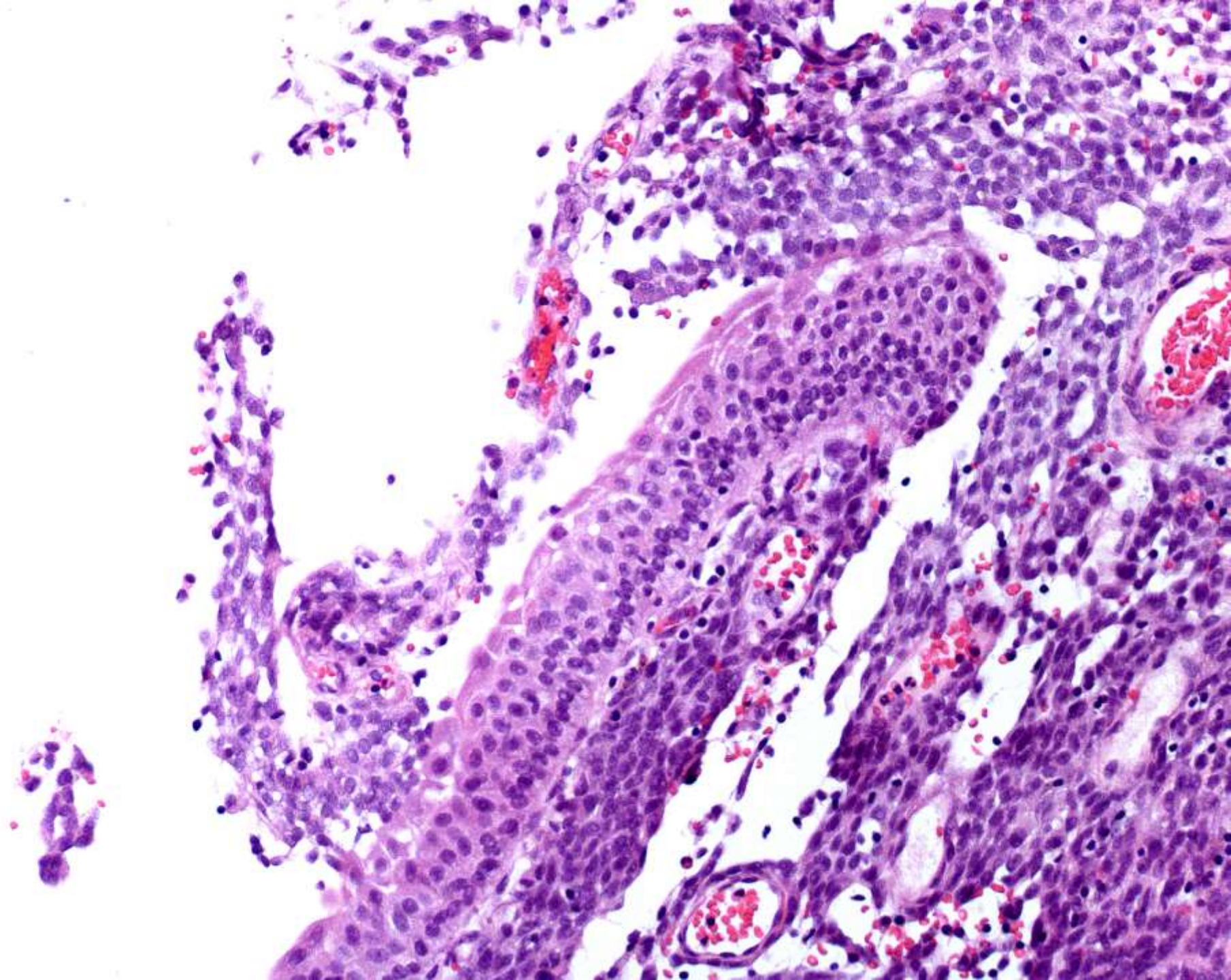


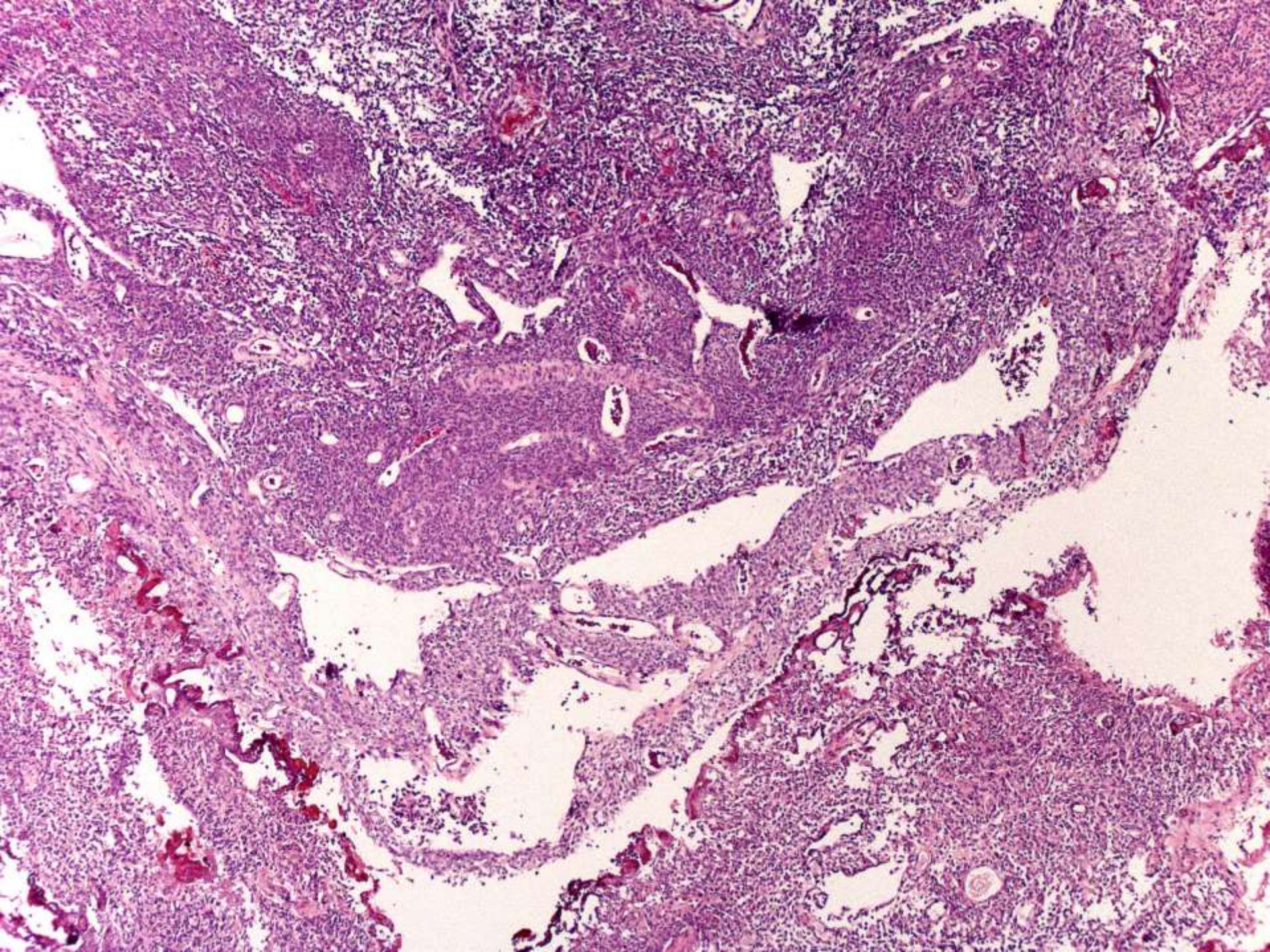


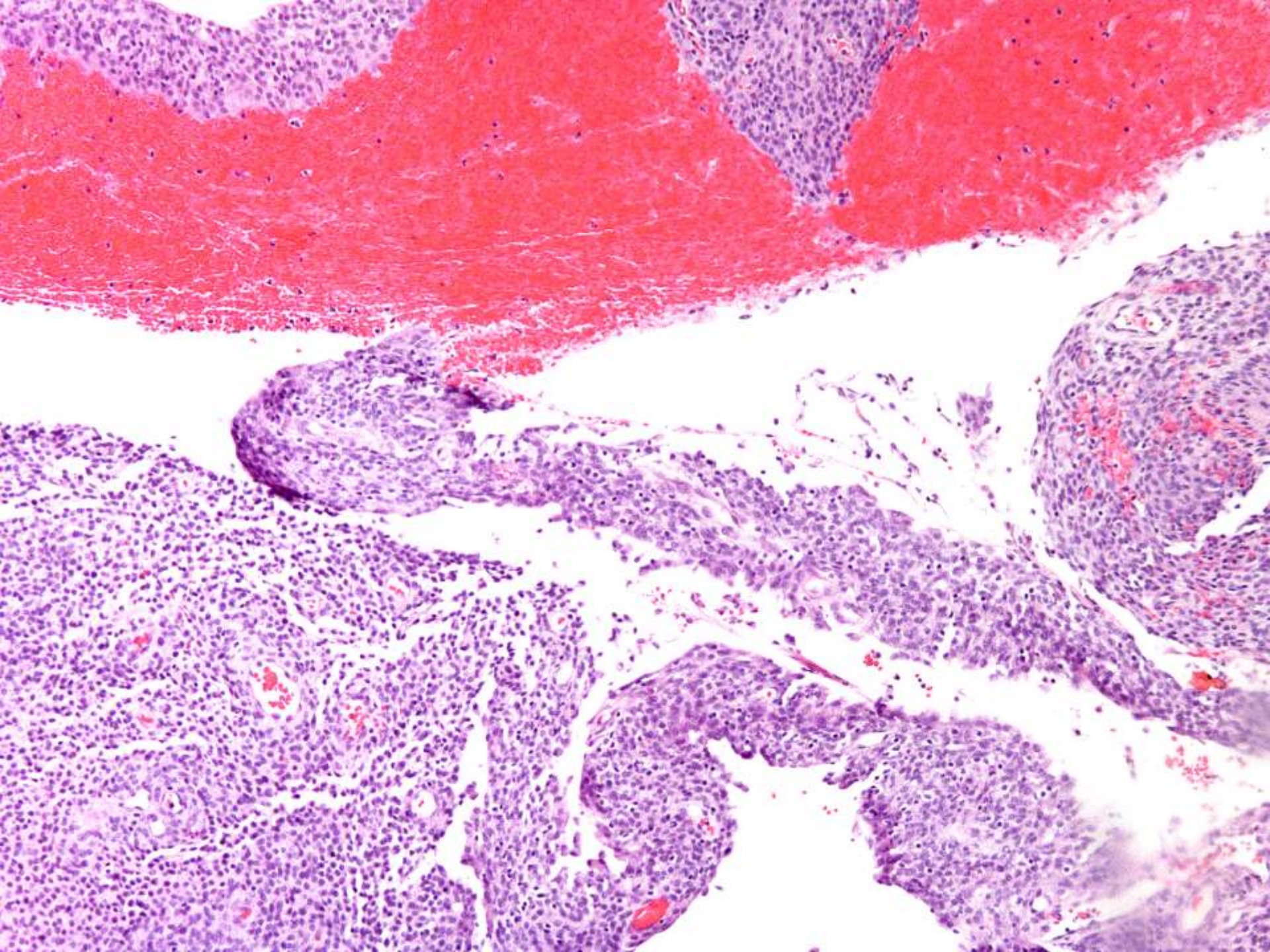
PSA [diagnosis = prostatic adenocarcinoma involving bladder]

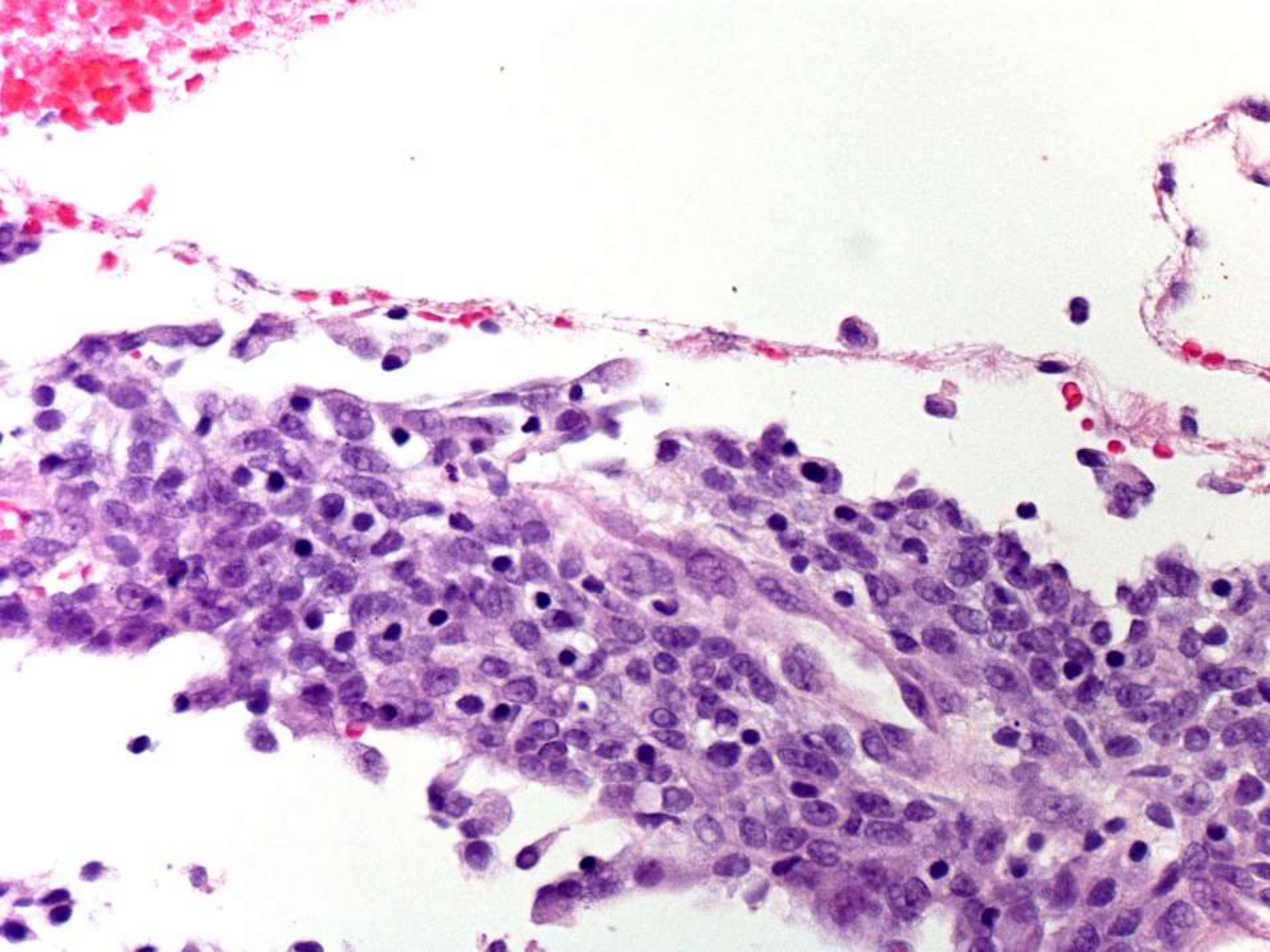
# Case: history

- Female 83 years
- “Bladder tumour > 5cm R lat wall. No curative resection
- 9.6g of chippings



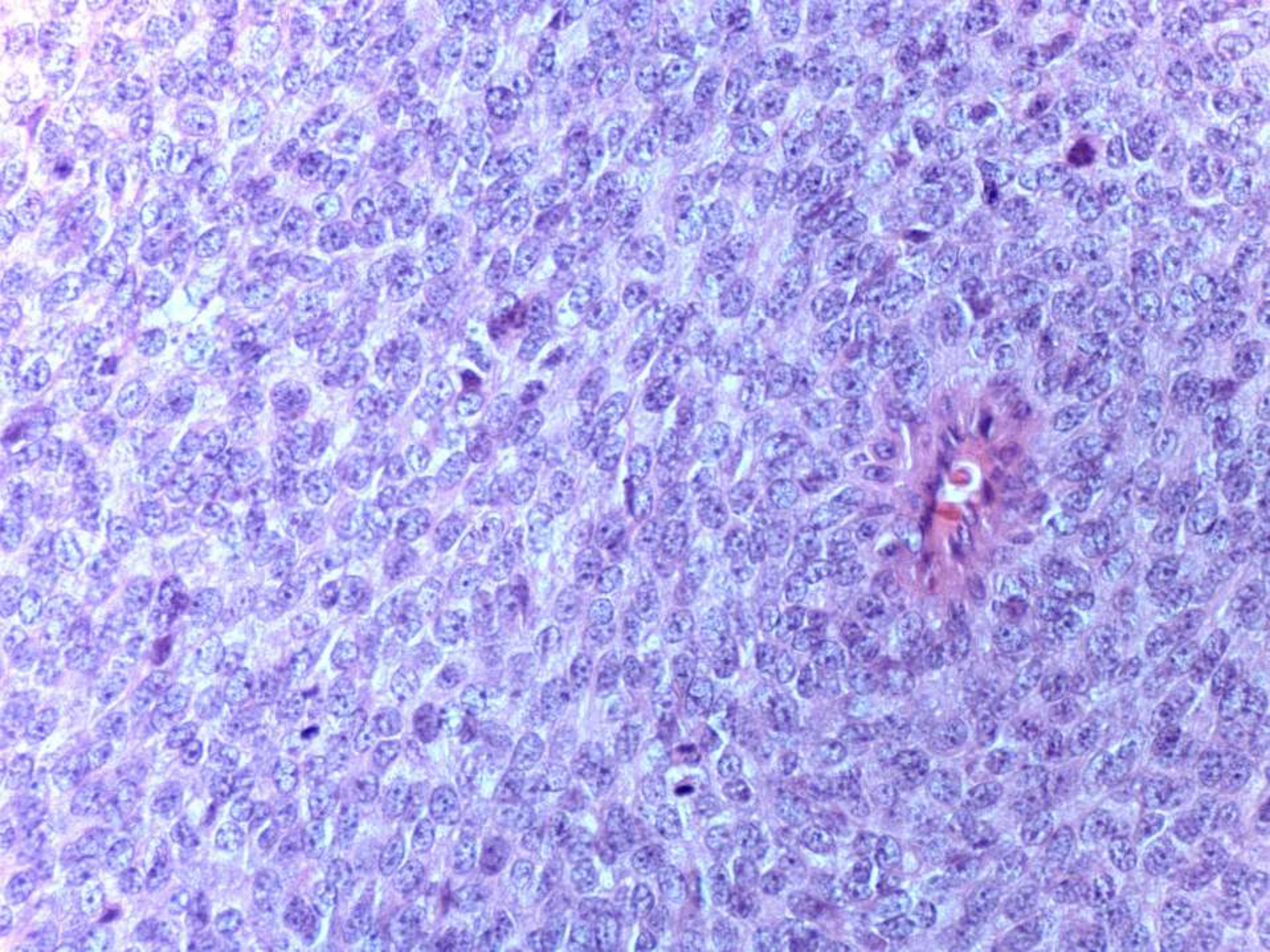


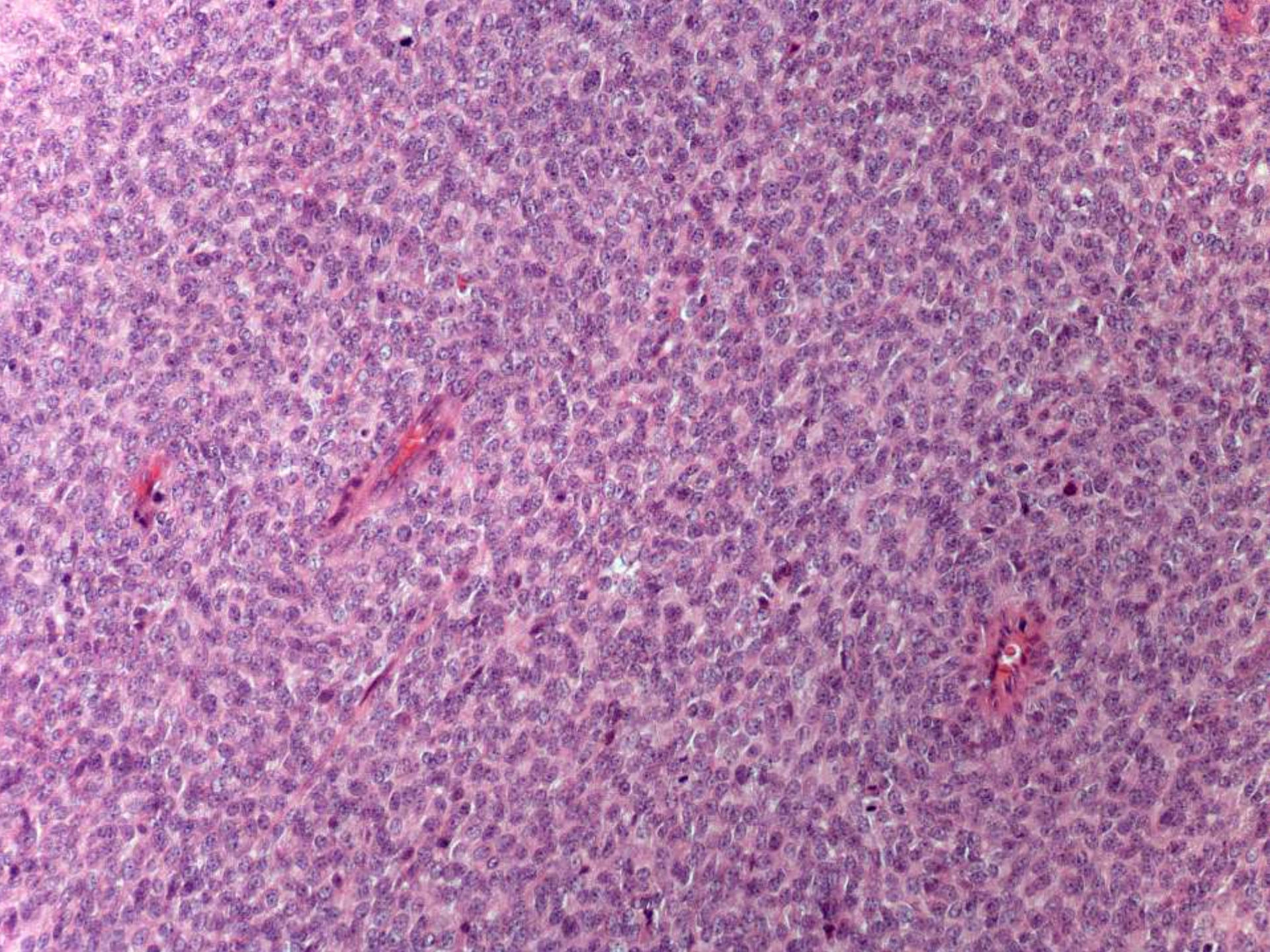




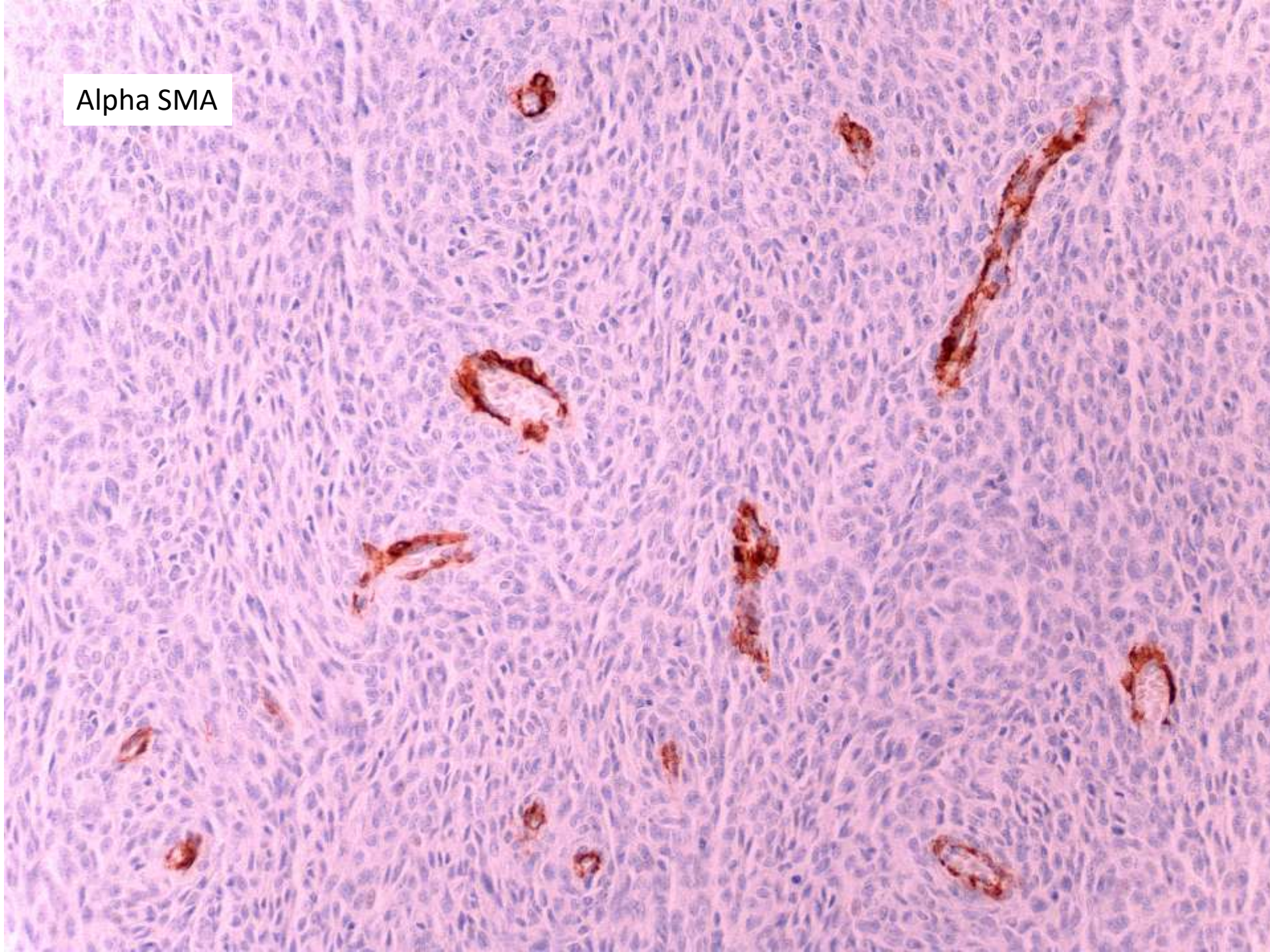
## 5 years previously

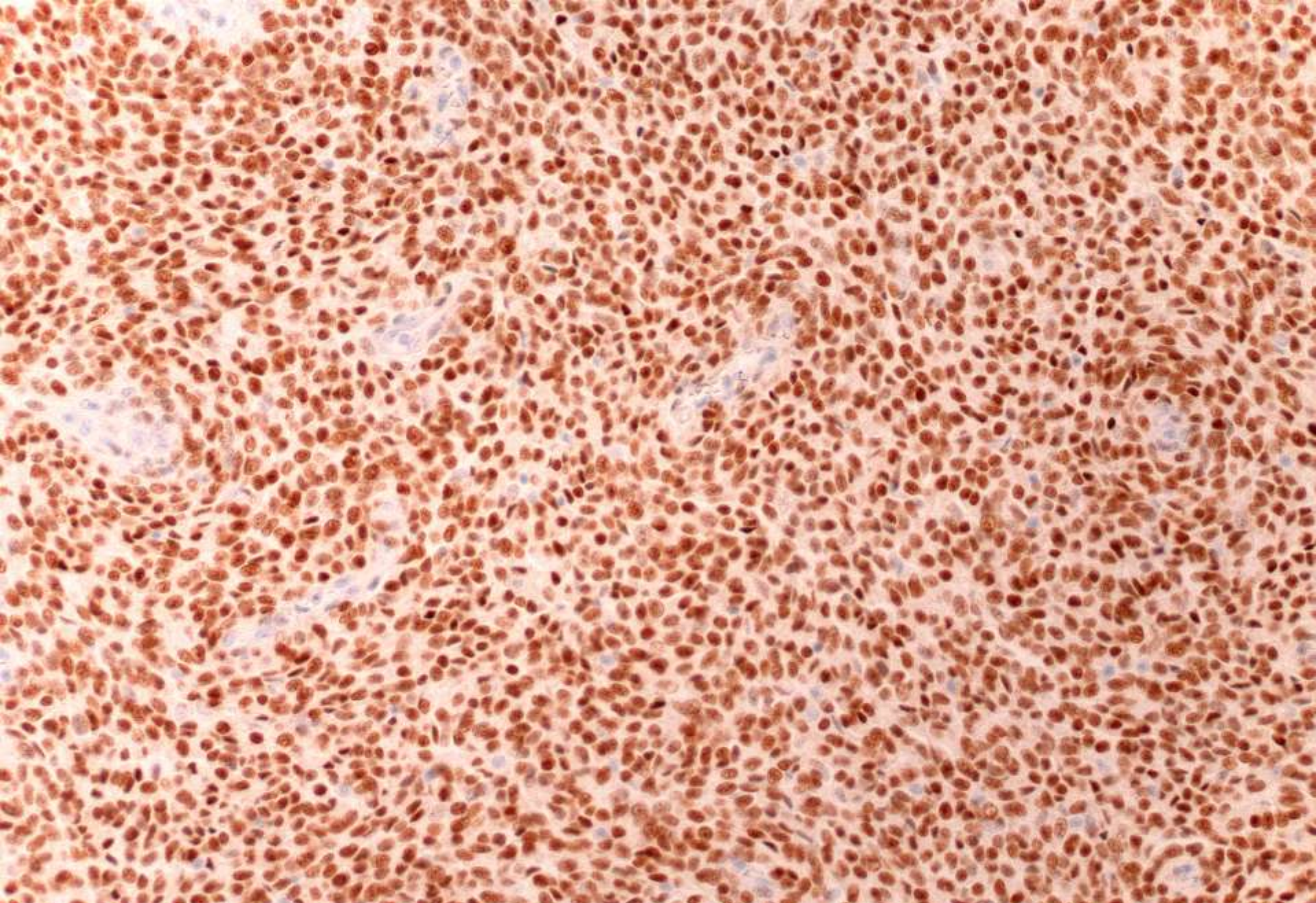
- TAH, BSO for large (2,117g, 190 mm max dimension) R ovarian tumour (appeared partly cystic with necrotic areas)



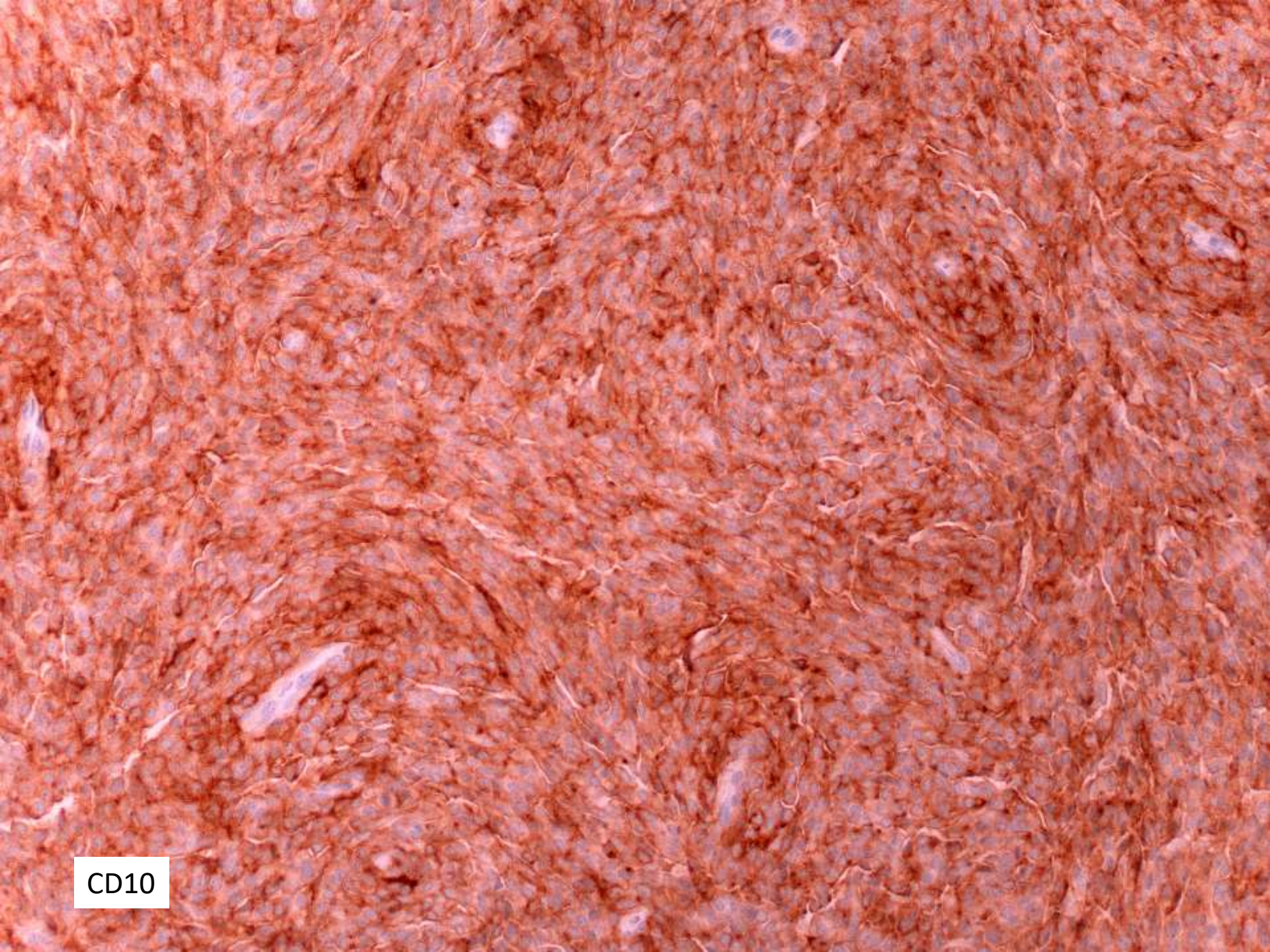


Alpha SMA





Oestrogen receptor; PR was similar and there was patchy staining for AR



CD10

Diagnosis: endometrial stromal sarcoma involving the bladder

# Selected references

Taylor AS, McKenney JK, Osunkoya AO, Chan MP, Al-Ahmadie HA, Spratt DE, Fullen DR, Chinnaiyan AM, Brown NA, Mehra R. PAX8 expression and TERT promoter mutations in the nested variant of urothelial carcinoma: a clinicopathologic study with immunohistochemical and molecular correlates. *Mod Pathol*. 2020 Jun;33(6):1165-1171.

Kryvenko ON, Epstein JI. Mimickers of urothelial neoplasia. *Ann Diagn Pathol*. 2019 Feb;38:11-19.

Lopez-Beltran A, Montironi R, Raspollini MR, Cheng L, Netto GJ. Iatrogenic pathology of the urinary bladder. *Semin Diagn Pathol*. 2018 Jul;35(4):218-227.

Han L, Gallan A, Paner GP. Patterns of Urachal Remnant Involvement by Urothelial Carcinoma: Intraluminal Noninvasive Spread Can Mimic a Deep-seated Bladder Invasion. *Am J Surg Pathol*. 2019 Apr;43(4):475-479.

Legesse T, Matoso A, Epstein JI. PAX8 positivity in nested variant of urothelial carcinoma: a potential diagnostic pitfall. *Hum Pathol*. 2019 Dec;94:11-15.

Feldman A, Borak S, Rais-Bahrami S, Gordetsky J. Secondary Malignancies of the Bladder: Avoiding the Diagnostic Pitfall. *Int J Surg Pathol*. 2018 Apr;26(2):120-125.

Kryvenko ON, Epstein JI. Pseudocarcinomatous urothelial hyperplasia of the bladder: clinical findings and followup of 70 patients. *J Urol*. 2013 Jun;189(6):2083-6.

Hameed O, Humphrey PA. Pseudoneoplastic mimics of prostate and bladder carcinomas. *Arch Pathol Lab Med*. 2010 Mar;134(3):427-443.



Thank you